



**YEDİTEPE UNIVERSITY**  
FACULTY OF MEDICINE



# OBSERVER MEDICAL STUDENT REPORT

CASE WESTERN RESERVE UNIVERSITY – UNIVERSITY HOSPITALS  
DIVISION OF CARDIAC SURGERY

AUGUST 1 - 31 2021

## STUDENT:

Ali Yenigün

Year 6 Medical Student

Yeditepe University – Faculty of Medicine

Istanbul/Turkey

## SUPERVISOR/MENTOR:

Alan Markowitz, MD

Assistant Professor of Surgery

Department of Cardiothoracic Surgery – Cardiac  
Division

Case Western Reserve University – School of Medicine  
Cleveland, OH/USA

## CHIEF OF CARDIAC SURGERY:

Marc Pelletier, MD, MSc, FRCSC

Professor of Surgery

Department of Cardiothoracic Surgery – Cardiac  
Division

Case Western Reserve University – School of Medicine  
Cleveland, OH/USA





# University Hospitals Harrington Heart & Vascular Institute

Division of Cardiac Surgery  
Division of Cardiovascular Medicine  
Division of Vascular Surgery &  
Endovascular Therapy

This work consists of my experiences in inpatient and outpatient clinics, surgeries and meetings, new knowledge I acquired by observing and researching in an academic institute, the Division of Cardiothoracic Surgery at Case Western Reserve University, University Hospitals. It also includes social activities I participated in Cleveland, OH.

# TABLE OF CONTENTS

Abstract	1
Daily Reports	4
-WEEK 1-	
August 2	5
Partial Anomalous Pulmonary Venous Return + Atrial Septal Defect	
Partial Anomalous Pulmonary Venous Return	
Aortic Valve Replacement	
Double Coronary Artery Bypass	
Cardiopulmonary Bypass	
August 3	8
Aortic Valve Replacement	
Mitral Valve Replacement	
Aortic Regurgitation: Clinical Manifestations, Diagnosis and Surgical Indications	
August 4	10
Aortic Valve Replacement	
Triple Coronary Artery Bypass	
Bioprosthetic vs Mechanical Valves	
August 5	11
Valve-Sparing Aortic Root Replacement	
Marfan's Syndrome	
August 6	13
Clinical Experience	
Constrictive Pericarditis	
-WEEK 2-	
August 9	15
TAVR Meeting	
STS Short-term Risk Score	
TAVR Clinic	
Myelodysplastic Syndrome	
Valve-Sparing Aortic Root Replacement	
August 10	18
Repaired Mitral Valve Replacement with a Mechanical Valve	
Pericardial Washout	
Mitral Regurgitation	
August 11	21
Triple Coronary Artery Bypass	
Grafts Used in Coronary Artery Bypass Surgeries	
Outpatient Clinic	
August 12	22
Triple Coronary Artery Bypass and Ascending Aorta Repair	
Interpreting Angiograms with Dr. Markowitz	
MitraClip Procedure	
MitraClip and The Ideal Anatomy for its Application	
August 13	25
TAVR	
Biventricular Pacemaker	

	-WEEK 3-	
August 16		26
Ascending Aorta Replacement		
Outpatient Clinic		
Triple Coronary Artery Bypass		
August 17		28
Echocardiography		
August 18		29
Coronary Bypass and Aortic Valve Replacement		
Type A Aortic Dissection		
August 19		30
Cardiac CT and MRI		
Coronary Calcium Scoring		
August 20		32
The Watchman Device		
Watchman Procedures in the Cath Lab		
	-WEEK 4-	
August 23		34
Maze Procedure		
Checking Up on Post-Op Patients in the ICU		
August 24		35
Surgical Experience: CABG, Aortic Valve and Annuloplasty Ring Implantation and Repair		
HAART Annuloplasty Ring		
August 25		37
Aortic Valve Replacement		
Aortic Stenosis: Clinical Manifestations, Diagnosis, and Indications for Valve Replacement		
August 26		39
Left Ventricular Assist Device Placement		
Left Ventricular Assist Devices (LVAD) and their Clinical Use		
August 27		40
Ascending and Hemiarch Aorta Replacement and Debranching		
	-WEEK 5-	
August 30		41
ECMO Discontinuation		
TAVR Clinic		
NYHA Classification		
Mitral Stenosis		
August 31		45
Triple Coronary Artery Bypass		
Farewell to the Cardiac Surgery Team		
Cleveland, OH		47
Cleveland		48
University Circle and Little Italy		50
Downtown		53
References		55
Figure References		57



## DAILY REPORTS

## August 2<sup>nd</sup> – Monday:

### Surgical Experience #1: Partial Anomalous Pulmonary Venous Return + Atrial Septal Defect

After a couple of hours of the front desk staff and me trying to find my hospital badge, I was finally allowed into the OR to see my first operation of my month in Cleveland, and to my luck it was an interesting case: a partial anomalous pulmonary venous return (PAPVR) and concomitant atrial septal defect (ASD) repair. Dr. Yasir Abu-Omar, who I met the day before, and Dr. Yakov Elgudin were the surgeons of this case. Because I came only to observe, the surgeons allowed me to put a gown on, while keeping my arms inside to not touch anything. With a sterile gown on and little or no distance from the operating table, I got a perfect view of the surgery. The patient was a female in her fifties, which was quite unusual, as congenital cardiac anomalies are diagnosed and treated in the early years of life.

After establishing cardiopulmonary bypass, the surgeons opened the right atrium to visualize the return anomaly and the ASD. After locating them, they used a single bovine pericardium and shaped it with scissors to patch the anomalies. After patching, they closed the right atrium, allowed blood to flow back into the heart and check the hemodynamics using transesophageal echo (TEE) to see if the anomalies were properly sealed, which they were. The patient, then was removed from bypass and closed.

### Partial Anomalous Pulmonary Venous Return <sup>1</sup>

The PAPVR is a left-to-right shunt anomaly, in which one or more, but not all pulmonary veins return the blood from the lungs back to the right atrium (RA) instead of the left (LA), causing mixing of oxygenated and non-oxygenated blood and volume overload on the right side of the heart. Although PAPVR can present as an isolated cardiac anomaly, it may occur with ASD in up to 3% of the patients, most commonly the sinus venosus type ASD. PAPVR can also present as a manifestation of Turner Syndrome.

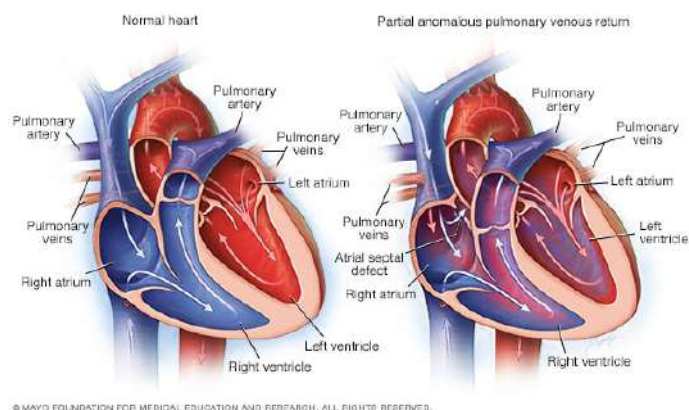


Figure 1: Normal heart vs PAPVR

Echocardiography, preferably transesophageal, is the most used method for a diagnosis of PAPVR. Right-sided chamber enlargement are the most conspicuous findings. In addition, dilated superior vena cava (SVC), inferior vena cava (IVC) or innominate veins may be among findings that should make a physician put PAPVR on list of differential diagnoses. Cardiac CT can be another imaging modality to diagnose or confirm PAPVR. It can provide additional anatomic details, including enhanced visualization of the pulmonary vasculature.

## Surgical Experience #2: Aortic Valve Replacement

## Surgical Experience #3: Double Coronary Artery Bypass

### Cardiopulmonary Bypass<sup>2,3,4,5</sup>

The cardiopulmonary bypass (CPB) is without a doubt, one of the most crucial steps in most cardiac surgeries. It enables the surgeons to work on the heart by emptying it and preventing it from beating. To achieve that state, the blood returning to the left atrium must be diverted to an external machine, oxygenated, and brought back to the body through aorta, which eventually perfuses the organs. There are specific steps to follow to ensure a safe and reliable cardiopulmonary bypass:

1. Anticoagulation infusion before bypass
2. Aortic cannulation
3. Venous cannulation
4. Cardioplegia cannulation and LV vent placement
5. Maintaining the bypass
6. Coming off bypass

1. Heparinization of the patient is the first step before starting with cannulation. The textbook dose is 300-400 units/kg. In surgeries I observed in, dose of 12,000-20,000 units of heparin were administered. The state of anticoagulation must be checked before proceeding with the operation, for which activated blood clotting time (ACT) is used for confirmation. The minimum acceptable value of ACT >400 seconds. In most patients this threshold can be passed with a single heparin infusion. In some patients, who are resistant to heparin due to weight, antithrombin III deficiency, elevated factor VIII or liver failure, additional heparinization may be required, depending on the ACT.

2. Aortic cannulation is the placement of the tube that brings back oxygenated blood from the bypass machine. The optimal location for the cannula is distal to the aortic clamp and proximal to the brachiocephalic trunk (innominate artery). After the placement, the surgeon checks for any air bubbles present in the tubes, which there usually is. These bubbles must be eliminated to prevent occlusion of any arteries in the body. The surgeon usually does that by hitting the tubes with a clamp to elevate the bubbles towards the valve of the cannula, and then drains a few milliliters of blood to expel the air bubbles with it. Then the arterial line is tested by the perfusionist by starting the flow and monitoring any unexpected increase in the arterial line pressure.

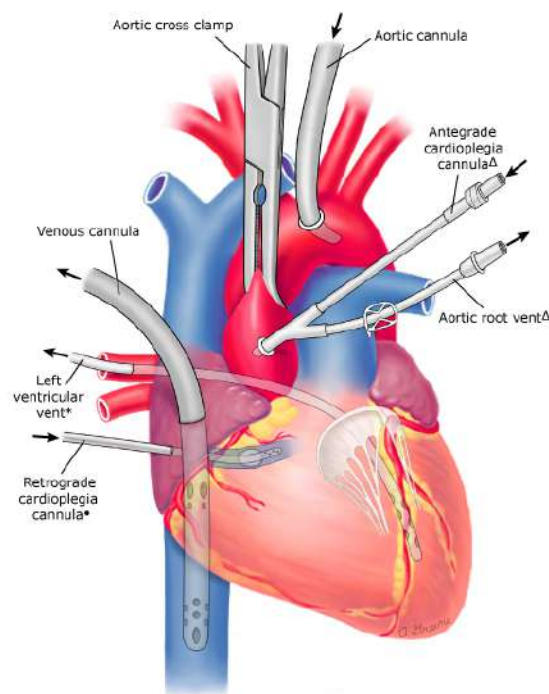


Figure 2: Intracardiac and Vascular Cannule Utilize

3. The other component of the blood diversion is the venous cannulation. The cannulas placed either into both venae cavae or just the right atrial appendage, depending on the structures being operated on.

4. The last cannula to be placed into the body is for the delivery of cardioplegia, a solution very concentrated in potassium to medically arrest the heart. There are two routes of cardioplegia: antegrade and retrograde. The antegrade cardioplegia is infused from the ascending aorta, proximal to the aortic clamp, whereas retrograde cardioplegia is administered through a cannula placed into the coronary sinus. The preference of one over the other depends on the surgeon's preference and the type of operation. As an example, I've seen Dr. Markowitz prefer retrograde cardioplegia exclusively, while Dr. Hussian elected for antegrade cardioplegia, and Dr. Abu Omar opted to use them both interchangeably. A vent into the left ventricle (LV) is also placed to prevent LV distension, usually caused by antegrade cardioplegia delivery in concomitant presence of aortic insufficiency.

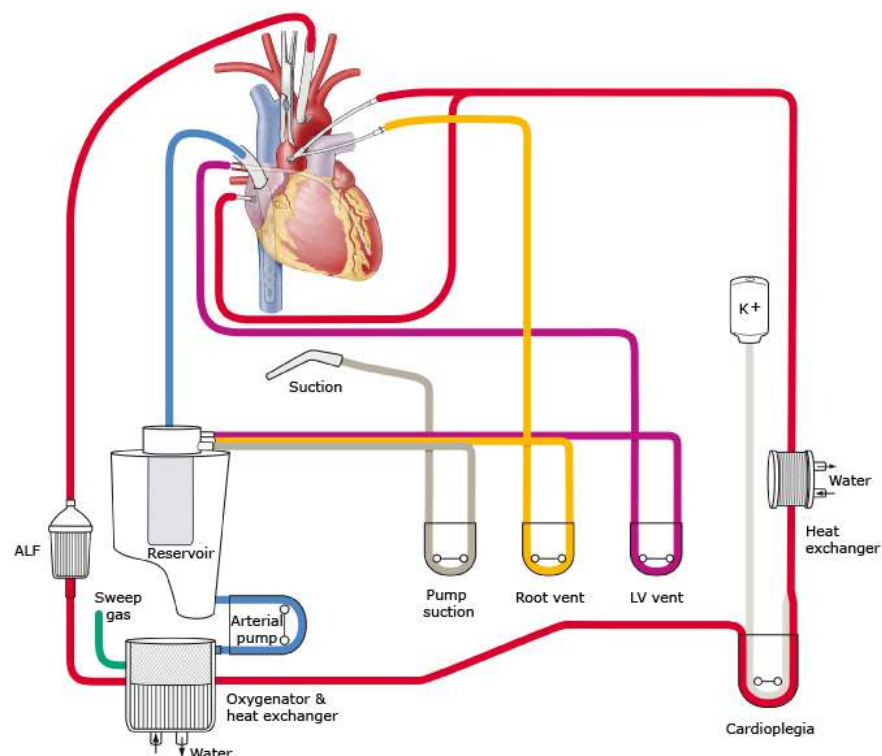


Figure 3: CPB Setup

5. Maintaining the CPB is essential for a smooth procedure. The flow rate during CPB is 2.2 to 2.4 L/min/m<sup>2</sup>. Target mean arterial pressure (MAP) is 50-80 mmHg. Arterial pO<sub>2</sub> is maintained at 150-250 mmHg, while venous oxygen saturation (SvO<sub>2</sub>) should be maintained >75%. These values remain dynamic throughout the surgery. The MAP, as I observed in surgeries usually stagnated between high 50's and low 60's. However, this value episodically rose above the limit when inadequate anesthesia was administered, and went below the range, which would then be treated by increasing pump flow rate. Cold cardioplegia is often used in cardiac surgeries to induce hypothermia on the patient to protect the brain and other organs during the bypass, by decreasing the metabolic demands of these organs. The target temperature for separation is 37°C at the nasopharyngeal site, after rewarming the patient, which can take a long time depending on the degree of hypothermia. In one of the surgeries I observed in, it took approximately 75 minutes to rewarm the patient, before separating them

from bypass. Other parameters the perfusionist regularly monitors every 30 minutes are urinary output (UOP), hemoglobin (Hb) and hematocrit (Hct), glucose and electrolytes. The UOP is monitored to affirm the patient is not oliguric, blood is transfused to the patient if Hb falls below 7.5 g/dL, insulin is administered if glucose remains elevated above 180 mg/dL, and electrolytes, such as potassium calcium and magnesium are always kept an eye on. 100 mg bolus of lidocaine is administered to the patients before aortic clamp is removed to prevent arrhythmias.

6. Weaning from bypass requires following a particular checklist. The patient must have a nasopharyngeal temperature of at least 37°C. There shouldn't be any air left in the cardiac chambers, which is viewed using transesophageal echo (TEE). There was almost always air in the heart, in the cases I observed. To eliminate it, the patients were placed into Trendelenburg position, and the surgeon squeezed the heart rapidly to dissipate the air bubbles. The heart rate must be within acceptable range with sinus rhythm. Adequate ventilation and oxygenation must be restored. Blood levels and electrolytes must be corrected. After ensuring the patient is fit to be weaned from bypass, protamine is infused to reverse the effects of heparin (this step may be performed earlier depending on the surgeon), the surgeon removes the catheters and cannulas and places epicardial pacing wires.

## ○ August 3<sup>rd</sup> – Tuesday:

### **Surgical Experience #1: Mitral Valve Replacement**

### **Surgical Experience #2: Aortic Valve Replacement**

#### **Aortic Regurgitation: Clinical Manifestations, Diagnosis and Surgical Indications <sup>6</sup>**

Aortic regurgitation (AR) is the inadequate coaptation of the leaflets, therefore causing a leakage back into the left ventricle. The etiology can be related to either the valve leaflets or the aortic root and the disease can be classified as acute or chronic. Chronic AR is the more common type, mainly caused by rheumatic heart disease in developing countries, whereas aortic root dilation, bicuspid aortic valve and calcific valve disease are the leading pathologies in developed countries. Acute AR is much rarer, caused by acute aortic dissection or infective endocarditis.

The main issue AR provokes on the heart is volume overload. The blood regurgitates back into the LV during diastole, mixing with forward-moving blood coming from the LA and fills the chamber more than its capacity. The result of this overload is compensatory eccentric hypertrophy: the thickening of the left ventricular myocardium with dilation of the chamber.

AR remains asymptomatic in most patients for years. When symptoms arise, they are characterized by angina, palpitations, exertional dyspnea, and symptoms of heart failure (HF), like orthopnea, paroxysmal nocturnal dyspnea, and pulmonary edema.

Physical examination may reveal a wide variety of signs. Arterial pulse and related finding are the most characteristic signs of AR:

- De Musset sign – head bobbing with heartbeat,
- Corrigan pulse – collapsing pulse characterized by a rapidly rising and falling arterial pulse due to wide pulse pressure,
- Duroziez sign – bruit heard when femoral artery is compressed,
- Quincke sign – capillary pulsations in fingertips,
- Müller sign – systolic pulsations of the uvula,

are among popular textbook signs of AR, although they have variable specificities.

Austin Flint murmur (or Aortic Failure murmur, as my professor used to call it) is the mid-to-late diastolic murmur heard at the apex, attributed to the mixing of forward and backward flowing blood in the LV. Precordial palpation may reveal forceful systolic impulse due to LV enlargement.

Echocardiographic findings are the key in diagnosis of AR. Findings could show an aortic root aneurysm, ascending aortic aneurysm or isolated aortic regurgitation. LV end-systolic and end-diastolic volumes are increased with normal ejection fraction, until LV decompensates. Three main parameters to assess the severity of AR are: vena contracta – the widest part of the regurgitant blood when it disperses in LV, effective regurgitant orifice area (EROA) and volume of the regurgitant blood. Severe aortic regurgitation is identified by vena contracta of  $>6$  mm, EROA of greater than or equal to  $30 \text{ mm}^2$  and regurgitant volume of more than 60 mL.

Table 1: Severity of AR Based on Echocardiographic Findings

	Mild	Moderate	Severe
<b>Vena contracta</b>	$<3$ mm	3-6 mm	$>6$ mm
<b>EROA</b>	$<10 \text{ mm}^2$	$10\text{-}30 \text{ mm}^2$	$>30 \text{ mm}^2$
<b>Regurgitant volume</b>	$<30$ mL	30-60 mL	$>60$ mL

Treatment for AR is composed of two parts: medical and surgical.

Medical therapy consists of vasodilators and diuretics. The underlying mechanism is decreased the pressure of the blood flowing through aorta and regurgitating back into the LV by aortic vasodilation. Drugs that decrease heart rate are not preferred, as the faster the heart pumps blood, the less time the blood is allowed to regurgitate.

Surgery is indicated in symptomatic patients, asymptomatic patients with  $\text{EF} < 50\%$  and patients undergoing heart surgery for other underlying cause, such as aortic dilation or CABG. The main preference is repair of the native valve, rather than replacement, in order to prevent the patient from a state of anticoagulation use brought by mechanical valve or requiring an additional valve replacement in the future, due to shorter lifespan of bioprosthetic valve.

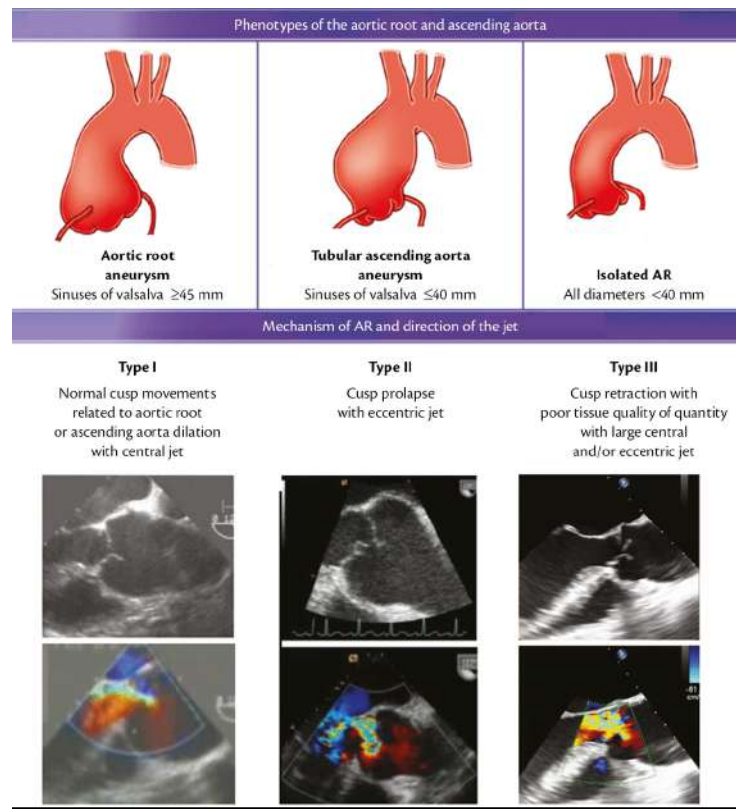


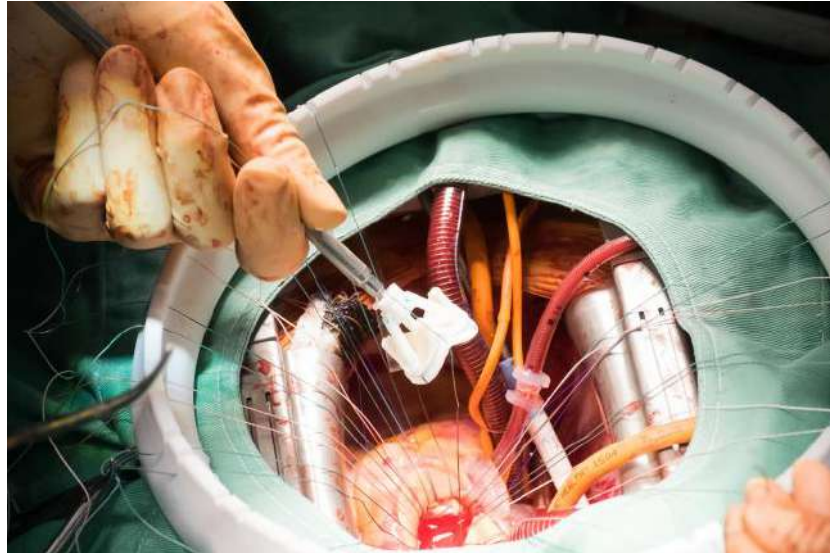
Figure 4: Types of aortic regurgitations based on etiologies

## August 4<sup>th</sup> – Wednesday

### Surgical Experience #1: Aortic Valve Replacement:

Unlike the other days of the week, cardiac surgeries start at 8 am on Wednesdays. Looking at the roster, I saw it was going to be a day concentrating on valve replacements. The first operation of the day was of a 61-year-old male patient, who had a calcified aortic valve, precipitated by the presence of its bicuspid structure. Due to the degree of calcification and the severity of the stenosis, a valve repair was out of question, and there was no option but to replace it.

The surgeon of this operation was Dr. Abu-Omar. He arrived at the operating room just as the patient was put under anesthesia, draped and the equipment was made ready. He made a vertical midline incision over the sternum, used the cautery (Bovie) mark the line for sternotomy. After cutting the sternum open with the saw, Dr. Abu-Omar and the surgical assistant pulled on the dissected sternum to opposite directions of each



*Figure 5: Surgeon sliding the replacement valve in place*

other. With the mediastinum open the pericardium was exposed. They cauterized the non-visible bleeding blood vessels, placed a sponge on the sides of the halves of the sternum and expanded the surgical site by using a retractor. He dissected the pericardium, aspirated the pericardial fluid, and ultimately exposed the heart. Then they started placing the cannulas to the appropriate sites: aortic canula to the distal ascending aorta, venous cannula to the right atrial appendage and both antegrade and retrograde cardioplegia cannulas. After Dr. Abu-Omar, the anesthesia specialist and the perfusionist agreed that they weren't anything preventing them from going on bypass, the cross-clamp was placed, and the cardiopulmonary bypass was initiated.

Because the aortic valve needed to be replaced, a transverse incision had to be made on the proximal ascending aorta. Using a measuring ring, the appropriate-sized aortic valve graft was chosen. The new valve was made from bovine pericardium. Dr. Abu-Omar started passing sutures first through the annulus of the graft, then the annulus of the patient's aortic valve. After he repeated that for 12 times, he and the surgical assistant gently slid the replacement valve in place, and then used the Cor-Knot device to fix the sutures in place. They visually checked the competency of the valve by pouring water over to it and seeing if it held up, which it did.

The surgeon decided to close the heart, take the patient off bypass, and close the mediastinum. The anesthesiologist used the TEE to see if the new valve was leaking centrally or periannularly. The valve looked to be in perfect shape, the blood flow through the valve was normal, and it was decided that the surgery was over.

## Surgical Experience #2: Triple Coronary Artery Bypass

### Bioprosthetic vs Mechanical Valves

The cases of valvular diseases I saw since coming to UH all required replacements, instead of repairs. The patients and surgeons all opted for bioprosthetic valves. While that had been the case in the last two days, some patients are more suitable for mechanical valves. Both have their pros and cons over the other, but in the end, patients' age, concomitant health issues and preferences are all key factors in deciding which type of valve is the best for the patient.

Mechanical valves are made from sturdy materials that are durable for very long periods of time. They were designed to last a lifetime. While the durability is key advantage of mechanical valves over bioprosthetic, the issue of thrombus formation remains a huge disadvantage. Patients opting for mechanical valves must be on anticoagulation therapy for the rest of their lives, to prevent strokes or emboli to the systemic circulation. Another important disadvantage is, in rare cases which the valves would have to be repaired, the only option would be open surgery. A young patient would a better fit for this type of valve, as the mechanical valve will last them a long time and not require re-surgery later. If the patient also has a condition which requires them to be on anticoagulation therapy, such as atrial fibrillation, it makes a mechanical valve an even better option.

Bioprosthetic valves are made from pig valves or bovine tissues. They typically last about 10-20 years. The beauty of biological valves is, because they resemble human tissues, they don't require anticoagulation therapy. In cases which the valves require repairs, transcatheter approach is possible without having to open the chest. Combining the length of durability and lack of need for additional medical therapy, bioprosthetic valves are better for older patients, who would otherwise be more vulnerable to the bleeding side effects of anticoagulants.



Figure 6: Mechanic and Tissue Mitral Valves

## August 5<sup>th</sup> - Thursday

### Surgical Experience: Valve-Sparing Aortic Root Replacement (David Procedure)

Dr. Alan Markowitz came down to UH Main Campus to perform valve-sparing aortic root replacement (David Procedure) on an 18-year-old patient with Marfan's Syndrome, who also happened to be a Jehovah's witness. Both parents and the sibling of the patient were also suffering from the Marfan's Syndrome. The patient had an aortic root diameter of 48 mm and considering the fact that the sibling also had needed to undergo the surgery a year ago, it was a clear surgical indication for this patient.

The patient being a Jehovah's witness meant that no blood products could be transfused if need arose, and no animal-based products were allowed to be used. This meant that Dr. Markowitz and the team had to be extra careful about blood loss.

The steps of the David procedure is as follows:

1. Cannulation of the right-sided subclavian vessels.
2. Clamping of the roots of the branches of the arch of aorta
3. Initiating cardioplegic arrest
4. Transection of ascending aorta 3mm above the commissures, while preserving the valvular attachments.
5. Transection of the coronary arteries from the aorta.
6. End-to-end anastomosis of ascending aorta graft to the aortic arch.
7. Placement of Valsalva graft.
8. Pouring water on the aortic valve to see if it holds up.
9. End-to-side anastomosis of coronary arteries to the Valsalva graft.
10. End-to-end anastomosis of the Valsalva graft to the ascending aorta graft.
11. Assessing the surgical result with TEE.
12. Weaning the patient from cardiopulmonary bypass.

### Marfan's Syndrome <sup>7</sup>

An autosomal dominantly inherited syndrome, mainly caused by the mutation of the fibrillin-1 gene on chromosome 15. Many types of mutation patterns of the fibrillin gene is possible; those with exon-skipping pattern tend to cause a more severe type of the syndrome, whereas nonsense mutations yield to a milder course. Average life expectancy of a patient with Marfan's is 70 years.

In 10% of the patients with Marfan's, mutations of the TGFB1/2 receptor have been detected. No mutation in up to 10% of the patients with Marfan's' traits have been found.

Pathogenesis of the syndrome is still a topic of debate, but the most widely accepted theory is the increased bioavailability of TGFB in the tissues.

Histologically, fragmentation of the elastic laminae, cystic medial necrosis, fibrosis, and loss of smooth cell in arteries have been observed.

Clinical manifestations can be divided into two subgroups: cardiac and non-cardiac. Cardiac manifestations include aortic root dilatation, which is the most common cause of mortality in patients with Marfan's. Aortic root dilatation can be seen in up to 50% of children and 60-80% of the adults. The root is enlarged but is conversely stiff. Other cardiac problems include, aortic regurgitation, dilation of the other segments of the aorta, involvement of the

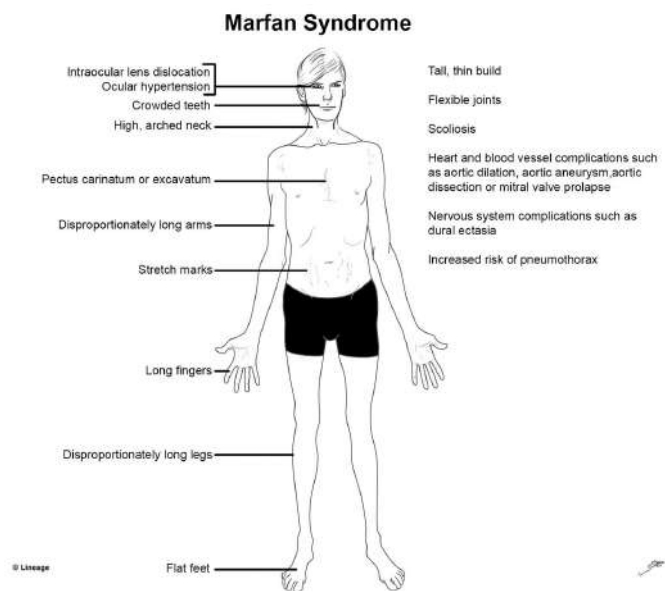


Figure 7: Phenotypic features of a patient with Marfan's Syndrome

pulmonary, carotid, or intracranial arteries, mitral valve prolapsus and aortic dissection (90% DeBakey type I).

Of the non-cardiac manifestations, skeletal abnormalities are the most conspicuous. Excess linear growth and disproportionately long extremities are textbook traits of those with Marfan's. Joint hyper-mobility, arachnodactyly, pectus deformities, kyphosis, scoliosis, and abnormal facial features make up the remainder of skeletal problems. Pectus excavatum is more commonly seen than the carinatum deformity; however, the carinatum deformity is more suggestive of Marfan's. Ectopia lentis with superior-temporal subluxation, myopia, emphysematous changes, increased tendency for pneumothorax, and striae on the skin are the remaining non-cardiac manifestations.

Differential diagnoses include Loeys-Dietz syndrome, Ectopia Lentis syndrome and homocystinuria.

- Loeys-Dietz syndrome differs from Marfan's syndrome with the presence of hypertelorism, split uvula, cleft palate, and spinal deformities. Otherwise, both syndromes have many common phenotypic features, including aneurysms and skeletal deformities.
- Ectopia Lentis syndrome does not cause Marfanoid habitus or aortic aneurysms.
- Homocystinuria can be differed from Marfan's syndrome by the direction which the lenses subluxate: inferiorly and nasally.

There are absolute and strong surgical indications:

- Aortic root aneurysm and maximum aortic diameter of >50mm (class I recommendation)
- Aortic root aneurysm, maximum aortic diameter of >45mm and presence of risk factors (class IIa recommendation)
  - o Risk factors include family history of aortic dissection, severe aortic/mitral insufficiency, aortic size increase of >3mm/year, desire for pregnancy

Medical therapy includes beta blockers (propranolol) to decrease the effect of blood pressure on the aortic root, angiotensin II receptor blockers (losartan), which antagonizes the effects of TGFB, and restriction of strenuous activity.

## ○ August 6<sup>th</sup> - Friday

### **Clinical Experience: Outpatient Clinic**

Dr. Markowitz asked me to come to UH Minoff Health Center to observe at the outpatient clinic. There was a mixture of post-op patients, as well as patients who were referred to Cardiac Surgery by their primary care physicians or cardiologists. Before seeing the patients, Dr. Markowitz showed me their echocardiographic images and reports, coronary angiograms, chest x-rays and MRI results, if they were present, and made sure I understood everything I saw.

Most of the post-op patients either had valve replacements or coronary bypasses; there were several other interesting cases too. Dr. Markowitz asked every patient if they were feeling fine, getting enough rest, doing basic exercises. He also answered any questions the patients and their relatives had. One interesting case we saw was a male patient in his late 50s, who had undergone pericardiectomy due to constrictive pericarditis. He had presented with distended neck veins and abdominal ascites. After an echo had been performed, it was

realized that he had a very thick pericardium and needed to undergo urgent pericardiectomy. The pericardium was measured to have a thickness of approximately 1.0 cm. Etiology was still being investigated.

As with the pre-op patients, Dr. Markowitz had a very clear set of procedures: First, he checked the patients' histories and all the available imaging techniques that were available and made sure they had received appropriate diagnoses. When seeing the patients, he asked what made them see their physicians in the first place. He asked about any symptoms they may have had and their effects on their lives. Then, with the help of a pen and a paper, he drew sketches of the heart and thoroughly explained exactly what was wrong with their patients. He talked about the appropriate surgical approaches, success rates, complications and how the first few weeks of their lives be after the operations. Finally, he made sure the patients understand everything he had just explained. (Dr. Markowitz also gave me a friendly reminder about making sure to add a copy of any sketches I may draw or things that I write to the patient folder.)

### **Constrictive Pericarditis <sup>8</sup>**

Constrictive pericarditis is the scarring and consequent loss of normal elasticity of the pericardial sac, impeding the cardiac filling.

Physiologically, inspiration decreases the intrathoracic pressure, leading to increased venous return to the right heart, which increases the right ventricle chamber size. A normal pericardium is adequately elastic to allow such expansion of the chambers of the heart. In constrictive pericarditis, due the loss. Of elasticity of the pericardium, the ventricles can only fill until mid-diastole, until the heart reaches the volume of the stiffened pericardium.

Constrictive pericarditis has a wide range of etiologies, of which idiopathic or viral infections make up more than half (42-61%) and post-cardiac surgery/iatrogenic causes account for 11-37% of the total cases. Radiation of the mediastinum after Hodgkin lymphoma and breast cancer, connective tissue disorders such as IgG4 disease, TBc is underdeveloped/developing countries, purulent pericarditis and miscellaneous causes make up the rest of the cases. Miscellaneous causes include malignancies, trauma to the chest, drug use, asbestosis, sarcoidosis, and uremic pericarditis.

Patients with constrictive pericarditis may present with peripheral edema, ascites, fatigue, dyspnea on exertion and chest pain. Upon examination, the physician is most likely to find signs of increased jugular venous pressure. Kussmaul's sign, which is the lack of decline of JVP on inspiration is one of the most characteristic signs. Pulsus paradoxus, pericardial knock and pulsatile hepatomegaly are among other findings.

Evaluation of the patients may reveal nonspecific ST and T wave changes on EKG, but the preferred diagnostic test for constrictive pericarditis is TTE. Increased pericardial thickness, dilation of the IVC and hepatic veins, atrial enlargement and halt in diastolic filling can be seen on two-dimensional echo. Increased velocity of ventricular filling and abnormally rapid diastolic filling are characteristic for constrictive pericarditis.

---

**August 9<sup>th</sup> - Monday****TAVR Meeting**

Monday mornings mean the TAVR meeting at the main campus, where cardiac surgeons and cardiologists meet to discuss patients who have valvular diseases and decide whether a patient is suitable for transcatheter or surgical approach, or if the patient is fit for any intervention at all. Dr. Guilherme Attizzani, an interventional cardiologist, Dr. Elgudin and Dr. Markowitz attended the meeting in person, while Dr. Marc Pelletier, head of Cardiac Surgery, Dr. Omar Hussian, and Dr. Gregory Rushing, both cardiac surgeons, joined via Zoom. It Because screen sharing was on the entire time, physicians that weren't physically there didn't have any trouble of viewing echo, angiograms, and lab results.

For each patient, certain information was shared with the entire team. Starting with the name, age, sex, and BMI, then diagnosis, followed by patient history. Symptoms and findings on examination had been shared by the physician who saw the patient in the first place. Due to the nature of the cardiac problems, almost every patient had a long list of comorbidities. The patient introduction is then continued with NYHA classification, frailty and STS risk scores, renal function tests, EKG and echo results and any additional incidental findings. With all the information laid on the table, the physicians reach a conclusion on what the interventional approach be, or whether the patient is even a candidate for intervention.

In the duration of two hours, twenty patients were discussed. While most of them were deemed fit for interventions, three of the patients had to be crossed of the list as the risk of mortality from any kind of approach was calculated to be too risky.

**STS (Society of Thoracic Surgeons) Short-term Risk Score <sup>9</sup>**

The STS Short-Term Risk Scoring system allows the physician to calculate a patient's risk of mortality and morbidities for the most commonly performed cardiac surgeries. As much as 64 variables are taken into account while calculating the risk score.

First, the procedure type is specified. After that, the values for each risk factor are entered to the system.

An STS predicted risk of surgical mortality of less than 4% is considered low risk, 4%-8% is intermediate risk and 8% or greater is high risk.

*Table 2: Parameters in STS*

Procedure type	WBC#	Mediastinal radiation	Endocarditis	Home O2	AFlu
Age	Plt#	Cancer within 5 years	Chronic lung disease	Previous cardiac intervention	3° HB
Sex	Creatinine	Family hx of CAD	Stenosis severity of RCA	MI time	2° HB
Race	Dialysis	Sleep apnea	Stenosis severity of LCA	HF time	Sick Sinus
Surgery date	Hypertension	Liver disease	Illicit drug use	NYHA class	VTach/ VFib
Weight	Immunocompromise	Unresponsive state	Alcohol use	Symptoms at time of admission	ADP inhibitor
Height	Perf. artery disease	Syncope	Pneumonia	Cardiogenic shock	ACE/ARB
Hematocrit	Cerebrovascular disease	Diabetes	Tobacco use	AFib	Beta blocker
Steroids	Glycoprotein IIb/IIIa	Resuscitation	# Diseased vessels	LAD distribution stenosis %	EF
AS, MS	AI, MI, TI	AV disease etiology	Incidence	Status	IABP insertion
ECMO	Catheter based assist device use				

### **Clinical Experience: TAVR Clinic**

Right after the TAVR meeting, Dr. Markowitz had a busy schedule with patients at the TAVR clinic. Patients started arriving at 9.30 am. Every single one of them had received a diagnosis of a valvular disease and were referred to Cardiac Surgery. Dr. Markowitz, as a cardiac surgeon and Dr. Attizzani, as an interventional cardiologist saw the patients together. Most patients had either aortic or mitral valve pathologies. Some in particular had additional pathologies that made for interesting cases.

A 71-year-old female patient presented with concomitant mitral and tricuspid regurgitation. She had a history of cholecystectomy, after which she became dependent on home O2. Being an ex-smoker and with a suggesting presentation, the physicians thought she could be suffering from COPD. Pulmonary function tests proved otherwise, as FEV1/FVC ratio was greater than 100%, but each value was in very low percentiles, which lead to a conclusion of a restrictive lung disease. Dr. Attizzani talked about the intervention of choice, which was MitraClip on both mitral and tricuspid valves. He told the success rate of the clipping the mitral valve was more than 99%. Dr. Attizzani also stated that, even the clip had not natively been designed for the tricuspid valve, it could still be applied, but with a little less success rate of about 95%.

Another patient that was particularly interesting was a 79-year-old male, who presented with a degenerated and calcified bioprosthetic aortic valve, which was Dr. Markowitz had implanted 12 years ago. What made the case complicated was a 12-year history of repeated blood transfusions in response to dropping hemoglobin levels. A

hematologist diagnosed the patient with myelodysplastic syndrome (MDS). Even though MDS isn't a contraindication against percutaneous valve replacement, it is a serious condition that must be followed very closely.

"Bleeding, stroke, coronary occlusion, infection and death." Speaking with the patients about every aspect of the planned intervention also requires a physician to list all the complications that can occur. Dr. Attizzani made sure the patients heard and understood the possible complications of the procedures, backing them with data. He made it very clear that, while the risk of complications remained less than 1%, they were not impossible.

### **Myelodysplastic Syndromes <sup>10</sup>**

MDS is a group of hematologic malignancies characterized by: 1. Clonal hematopoiesis 2. One or more cytopenias 3. Abnormal cellular maturation. In spite of sharing features with acute myeloid leukemia (AML), MDS differs by causing lower percentage of blasts in the peripheral blood and bone marrow - >20% in AML, whereas <20% in MDS. Clinical features depend on which type of blood cells the patient is cytopenic of. Anemia symptoms, infection and bleeding are the cardinal symptoms of MDS. Transformation to AML is a dangerous progression of the syndrome, the incidence of which varies across MDS subtypes.

MDS arise from unknown mutations in hematopoietic stem cells (HSC). The cause of these mutations are believed to be the result of chemotherapy agents, ionizing radiation or environmental toxins, such as benzene and tobacco. Familial MDS have also been reported in association with specific germline mutations

As with many hematologic malignancies, MDS occurs more commonly in older adults, with median age of presentation being 70 years. Incidence in males is more common.

Clinical presentation varies greatly by the type of cells affected.

- Cytopenias:
  - o Anemia – fatigue, weakness, exercise intolerance, angina, dizziness, cognitive impairment, fatigue out of proportion to the degree of anemia
  - o Leukopenia – predominantly bacterial infections, gingivitis, skin infections, hypogammaglobulinemia, hypergammaglobulinemia
  - o Thrombocytopenia – easy bruising, bleeding
- B symptoms (represent transformation to AML): night sweats, weight loss, fever
- Autoimmunity: chronic rheumatic heart disease, rheumatoid arthritis, pernicious anemia, psoriasis, pericarditis, pleurisy, iritis, peripheral neuropathy...
- Acquired HbH disease

Diagnosis:

- Blood smear:
  - o RBCs: normocytic or macrocytic, rarely microcytic. Ovalomacrocytosis, elliptocytes, tardrop cells, acanthocytes, basophilic stippling, H-J bodies.

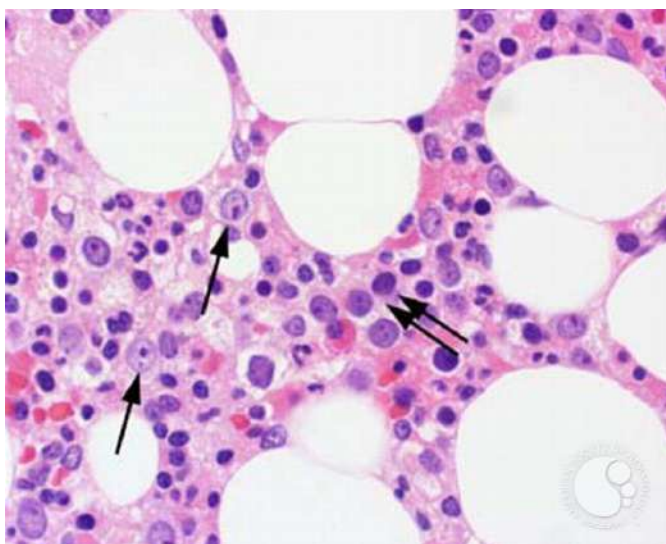


Figure 8: Bone marrow biopsy showing immature erythroid precursors

- WBCs: dysplastic neutrophils, reduced segmentation of granulocytes
- Bone marrow aspiration:
  - White cell precursors: increased myeloblasts, but *must be* <20%, Auer rods, impaired myeloid maturation
  - Red cell precursors: erythroid hyperplasia due to ineffective erythropoiesis; large and multilobularly nucleated precursor cells; vacuolated cytoplasm
  - Megakaryocytes: multiple dispersed nuclei, hypogranular megakaryocytes, small megakaryocytes
  - Fibrosis: in up to 50% of the patients.
- Immunohistochemistry

### Surgical Experience: Valve-Sparing Aortic Root Replacement (David Procedure)

With the TAVR meeting and clinic over at 11.30 am, Dr. Markowitz and I drove to UH Ahuja Medical Center for a yet another valve-sparing aortic valve replacement. The patient, undergoing surgery was a 49-year-old male with aneurysmal dilation of the aortic root and the arch. The root was measured as 5.23 cm. The patient also had a history of traumatic brain injury and paranoid schizophrenia. Due to his conditions, his mother was deemed as his legal guardian, from who consent for the operation was taken previous Thursday. The same set of procedure was followed as it was on Thursday: right subclavian vessels were cannulated, aortic arch was clamped from the branching points, ascending aorta was transected above the commissures, coronary arteries were transected from the aorta and an ascending aorta and Valsalva graft were anastomosed. At that point, I unfortunately had to leave early for an appointment.

## ○ August 10<sup>th</sup> - Tuesday

### Surgical Experience #1: Repaired Mitral Valve Replacement with a Mechanical Valve

I went up to the OR floor to see my first surgery in CMC this week. As I walked into the operating room, I saw a new face. A guy, about as tall as me, wearing a cap with Pokémon characters greeted me. His name was Cris Baeza, a final year medical student from Santiago, Chile. We had a small chat and exchanged numbers while the patient was being prepped for surgery.

The surgery was of a 49-year-old woman, who had her mitral valve replaced little over a year ago. Her repaired valve, extraordinarily idiopathically degenerated over the course of a year, and she had presented with mitral insufficiency. This patient, therefore required a valve replacement, and a mechanical valve was the sole option. Surgeons of this case were Dr. Pelletier and Dr. Hussian.

What made this surgery different from the others that I had watched in the last week was, I was going to see a sternum that has been operated on and sutured before. This brought

extra challenges to the surgeons. First was being, due to the altered structure of the sternum, the saw that was used to cut open the chest was different, and it had no safety mechanism as the saw the surgeons normally use for sternotomy; this caused a much higher risk of damaging the heart. A second challenge was to remove the metal sutures from the sternum. The third challenge was dissecting a diffusely fibrotic pericardium. After a pericardium is operated on, it heals by fibrosis and these fibers attach quite potently to the heart. It took Dr. Hussian around 20 minutes before he removed all the pericardial tissue to expose the heart.

The surgeons switched between antegrade and retrograde cardioplegia throughout the surgery. First, the degenerated valve was removed. Although I didn't get a chance to touch it, it was apparent that its consistency resembled more of a rubber than a valve. After the removal of the old valve, a mechanical one was implanted in place. After completion of the procedure, the anesthesiology team checked if the valve was functioning properly using TEE. At the end of the surgery, Cris and I both agreed that the most pleasing moment of the operation was the surgeons slowly sliding the valve in place.

### **Surgical Experience #2: Pericardial Washout**

The second surgery of the day was more of a minor intervention than a major surgery. The patient was 44-year-old male with massive pericardial effusion a week after aortic valve repair. The patient had been operated on for aortic stenosis and regurgitation. His history revealed shortness of breath and fatigue. He came back to hospital a week later with complaints of shortness of breath, fatigue and compression-like feeling in his chest. A quick echo revealed massive pericardial effusion, which required a pericardial washout. Dr. Hussian made a small incision a few centimeters inferior to the patient's xiphoid process. An aspirator was used to remove the collected fluid. Although I'm not sure if the entire fluid aspirated from the chest came from the pericardial sac, the total amount of fluid collected from the patient added up to 500 mL!

### **Mitral Regurgitation:** <sup>11, 12, 13, 14</sup>

Mitral regurgitation (MR) is one of the more common valvular diseases. Depending on the etiology of the disease, it can be classified into primary and secondary MR.

Primary MR is related to abnormalities of valve leaflets, chordae, papillary muscles, or the annulus. Degenerative mitral regurgitation (DMR) is the most common of all causes in this category. It is caused by either diffuse myxomatous disease (DMD) or fibroelastic deficiency (FED). FED is mostly localized to one segment and present with leaflet redundancy, thickening of the flail segment and histologically myxomatous degeneration. DMD lesions are more generalized and involves both leaflets. FED is more prevalent in the elderly population, whereas DMD is the disease of younger population. Rheumatic heart disease classically causes mitral stenosis, but mitral regurgitation is also a possible consequence in cases of severe inflammation of chordae and mitral leaflets. Infective endocarditis can result in vegetations, valve deformities and chorda rupture, which can eventually lead to MR.

Secondary (functional) MR is the result of pathologies of structures other than the valve or the supporting anatomy. Most common etiology in this class is myocardial infarction (MI). Systolic dysfunction and LV remodeling can cause restricted leaflet motion and coaptation failure. Additionally, papillary muscles may rupture and cause severe acute MR, which is life-threatening. Other pathologies leading to MR are dilated cardiomyopathy, hypertrophic cardiomyopathy, LA enlargement and subsequent mitral annulus widening as a result of AFib.

Most patients with MR are asymptomatic. If symptoms arise, dyspnea, palpitations, weakness, fatigue, and exercise intolerance would be things to keep in mind.

On auscultation of the heart, the classic heart sounds heard in MR are pansystolic murmur, radiating to the left axilla. Left systolic murmur can be heard on the apex if there is mitral valve prolapsus.

Chest x-ray may reveal LA and LV enlargement, although the degree of enlargement has no correlation with the severity of the regurgitation. The imaging technique for the diagnosis of MR is TEE, or cardiac MRI if the echo findings are suboptimal.

Table 3: Severity of MR Based on Echocardiographic Findings

	Mild	Moderate	Severe
<b>Vena contracta</b>	<3 mm	3-7 mm	>7 mm
<b>Proximal Isovelocity surface area (PISA)</b>	<0.5 mm <sup>2</sup>	0.5-1.0 mm <sup>2</sup>	>1.0 mm <sup>2</sup>
<b>Pulmonary vein flow</b>	Systolic dominance	Systolic blunting	Systolic reversal
<b>EROA</b>	<20 mm <sup>2</sup>	20-40 mm <sup>2</sup>	>40 mm <sup>2</sup>
<b>Regurgitant volume</b>	<30 mL	30-60 mL	>60 mL
<b>LA and LV size</b>	Usually normal	Normal/mildly dilated	Usually dilated

Treatment of choice for primary MR is surgery, either mitral valve repair or replacement. Both symptomatic and asymptomatic patients may be candidates for surgery:

- Symptomatic patients with severe primary MR with EF>30%
- Symptomatic patients with severe primary MR with EF<30%
- Asymptomatic patients with severe primary MR with EF 30-60%
- Asymptomatic patients with severe primary MR undergoing cardiac surgery for other pathology are candidates for concomitant mitral valve repair

The step is to decide whether the patient should undergo valve repair or replacement. As I learned from my attending at UH, the first option should always be preserving the native tissue of the patient and repairing the valve if the likelihood of successful repair is high. Otherwise, valve replacement is the appropriate choice.

Treatment of secondary MR depends on the underlying condition:

- Patients with ischemic MR are suggested to undergo mitral valve replacement with chordal sparing
- Patients with non-ischemic MR are suggested mitral valve repair if favorable results are expected. The choice is valve replacement if that's not the case

Transcatheter mitral valve repair is a minimally invasive option that should be evaluated in patients with moderate-severe or severe MR. At least 3 of the following criteria should be met for consideration:

- Pulmonary vein flow must show systolic blunting or reversal
- Color flow jet can be central and large, or eccentric and small
- Vena contracta should be >5 mm
- Regurgitant volume should be >45 mL/beat
- EROA of at least 30 mm<sup>2</sup>
- Regurgitant fraction >40%

+

- Ideal anatomy for mitral clipping (discussed in separate entry)

## August 11<sup>th</sup> - Wednesday

### **Surgical Experience: Triple Coronary Artery Bypass**

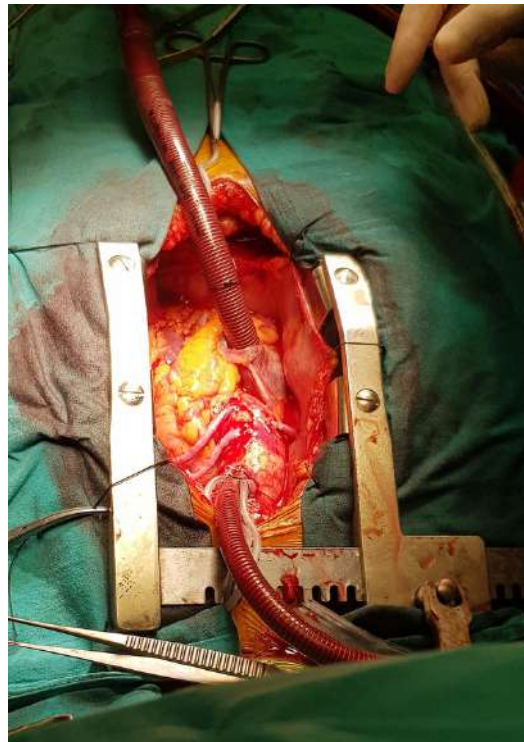
The only surgery for today was a triple bypass grafting. The patient was a 47-year-old male, who had occlusions in RCA, LAD and Cx arteries. Patient history revealed that he is a smoker and has history of CAD in his family. Before the surgery started, Dr. Rushing showed us the angiograms and help us interpret them. Two key points he gave were: (i) LAD can be identified by searching for the septal branches. (ii) If the LCA is supplying the PDA without having a direct branch to it, it is highly likely that the RCA is also occluded, and the supplying branches are collaterals forming from LCA over time by the process of angiogenesis. As grafts, bilateral internal mammary arteries and the left radial artery were acquired. Dr. Rushing was the surgeon who acquired the grafts. Because reaching the IMA's require meticulous work, it took a long time before the grafts were started to put in place, which is the part where Dr. Pelletier stepped in.

While heparin was being administered to the patient, Dr. Rushing explained to Cris and me the use of PF4 test. The PF4 test is the gold standard in diagnosing heparin induced thrombocytopenia (HIT). In HIT, IgG autoantibodies directed at platelet factor 4 (PF4) make a complex with heparin, which activates platelets to cause diffuse thromboses in arteries and veins. If the patient is positive for PF4 antibodies, anticoagulants like rivaroxaban or bivalirudin are preferred.

### **Grafts Used in Coronary Artery Bypass Surgeries**

Coronary artery bypass surgeries involve placement of grafts between the aorta and the affected coronary arteries. Both arteries and veins can be used as grafts. There are important differences between two types of grafts, which should be taken into consideration before proceeding with a bypass surgery.

Among the venous grafts, the great saphenous vein is the most used. Compared to arterial grafts, venous grafts have high failure rates. Patency of the veins is found to be dependent on the distal runoff of the bypassed coronary artery. Because the saphenous vein has a large diameter, its use in bypassing a larger coronary artery, like the LAD yields to high patency. Failure of venous grafts often is in the form of stenosis. Other complications include early later, and late occlusions. Early occlusions occur in the first 30 days of the bypass surgery, which has a prevalence of 10%. This complication is usually a result of technical failures, poor distal runoff, and hypercoagulability. Later occlusions, within the first 12-18 months after the bypass surgery are caused by platelet aggregation, growth factor secretion, reduced endothelial production of NO and prostacyclin, inflammation, foam cell accumulation, and intimal hyperplasia. Late occlusions are caused by development of lipid deposition and subsequent atherosclerotic-like



*Figure 9: A triple bypass surgery*

plaque formation. From the first to the sixth year after a bypass surgery, saphenous grafts obstruct at the rate of approximately 2 percent per year. The closure rate rises to 4 to 5 percent per year after that.

Arterial grafts are more reliable and durable than their venous counterparts. They have been associated with longer patency and higher patient survival rates. While preference of using multiple arterial grafts might sound feasible at first, there are some conditions that require some arteries to be left in their original locations: life expectancy of less than 10 years, obesity, dialysis, emphysema, poorly controlled diabetes. Patency rates for arterial grafts are 98% in the first 10 years. Most commonly used arterial graft is left internal mammary artery (LIMA). In cases where more than one arterial graft is needed, the second choice is usually either RIMA, or the radial artery. Use of radial artery requires further evaluation for adequate ulnar artery flow; classically, Allen test can be used to see if ulnar artery is adequate by itself to supply the hand.

### **Clinical Experience: Outpatient Clinic**

The second Dr. Pelletier scrubbed out of the surgery, he rushed to the outpatient clinic. Because surgery took longer time than he anticipated, the outpatients had to be pushed back by an hour. He had ten patients today, some which came for their follow up visits, while the remaining were sent for consultations by other fields. Dr. Pelletier and assigned me the task of talking to the patients and checking up on them before he saw them. He gave me a few key points to ask about: how the patient has been doing since the surgery, any complaints of chest pain, shortness of breath, syncope, any other complaints, how active the patients are... The patients were very friendly and eager to answer all the questions I had for them. When I was done talking to them, I shared all the information I gathered with Dr. Pelletier. Then we looked at the patients' notes from previous visits, chest x-rays, angiograms, and EKGs. When he was sure that he had all the necessary information he needed, Dr. Pelletier went to the outpatient rooms to meet the patients. Nearly everybody was doing fine and no longer required follow up visits to cardiac surgery.

## **August 12<sup>th</sup> - Thursday**

### **Surgical Experience: Triple Coronary Artery Bypass + Ascending Aorta Repair**

The only surgery, which I partly got to observe was a joint triple bypass and ascending aorta repair surgery, which Dr. Elgudin was performing. The patient was a 62-year-old male, who had occlusions in his LAD, Cx, and RCA. The chosen grafts were bilateral mammary and the left radial arteries. Although not aware of the exact dimensions, I was told the patient's ascending aorta was dilated as well, which was going to be repaired. The patient had a history of type-2 diabetes, chronic renal failure, and hypertension. He also had a history of stenting in his various arteries between years 2003 and 2013. Because the stents were occluded, it was time for a bypass surgery.

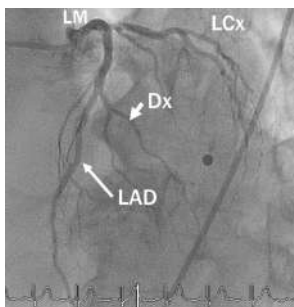
## Interpreting Angiograms with Dr. Markowitz



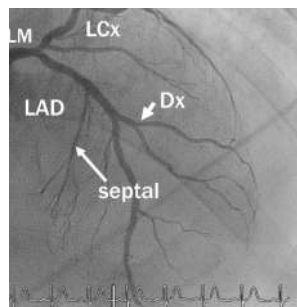
*Figure 10: Dr. Markowitz interpreting the angiogram of a patient*

After telling Dr. Markowitz that I had trouble understanding the views and the directions from which the angiograms are imaged, he agreed to teach me the basics of the angiography. Exiting the OR, we went directly to his office in the opposite wing of the hospital. He logged into the hospital system, loaded his patient list. I pulled up a chair and we started looking at the angiograms of the patients Dr. Markowitz had in the last two weeks.

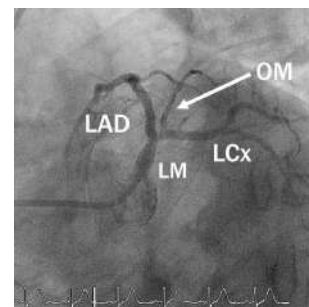
Dr. Markowitz first started explaining the views. He said, if I knew from which view I was looking at, the rest was easy. There were right anterior oblique views from different angles, left anterior oblique views from, again, different angles, and caudal (spider) views.



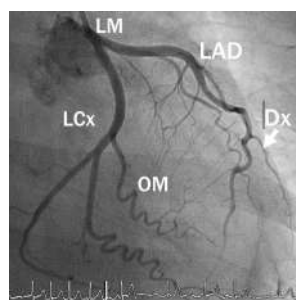
*Figure 11a: LAO cranial view*



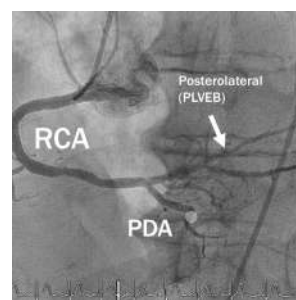
*Figure 11b: RAO view*



*Figure 11c: Spider view*



*Figure 11d: RAO caudal view*



*Figure 11e: RCA*

### Interventional Experience: MitraClip Implantation

An hour-and-a-half private lecture on angiogram interpretation by Dr. Markowitz was followed by an intervention that I was not expecting to see during my time at UH. I stepped out of the environment of blood and guts of cardiac surgery into the minimally invasive world of interventional cardiology. Dr. Attizzani was going to implant a MitraClip onto the mitral valve of a female patient in her fifties, with severe mitral regurgitation. Echocardiography revealed that the anatomy of her mitral valve was ideal for this intervention.

The main difference between interventional cardiology and cardiac surgery is, of course, the area which the physician works in. For a surgeon, it is the exposed mediastinum after the use of a saw to open the sternum. However, for a cardiologist, it is the small incision into the femoral vein. Every equipment that will be introduced to the patient's body enter through that small incision.

TEE is performed for confirmation of the exact location of where the clip is to be implanted. Interatrial septum is punctured for access to the left atrium. Once the septum is punctured, a guidewire is positioned into left upper pulmonary vein. Delivery sheath is placed into the left atrium. Then, the clip delivery system is advanced into the left atrium. This process requires TEE guidance to avoid any injury to the left atrial wall. The MitraClip is introduced through the sheath in closed position. The arms of the clip remain closed until passing through the mitral valve, which are reopened after reaching the left ventricle.

The clip must grasp the leaflets. Verification of the arms of the clip are done with fluoroscopy and TEE at the same time. Once the arms of the clip completely grasp the mitral valve leaflets, the clip is placed. The regurgitation is assessed with Doppler ultrasonography. If the position of the clip and the reduced level of regurgitation are found to be satisfactory, the delivery system is withdrawn from the patient.



Figure 12: MitraClip and its delivery system

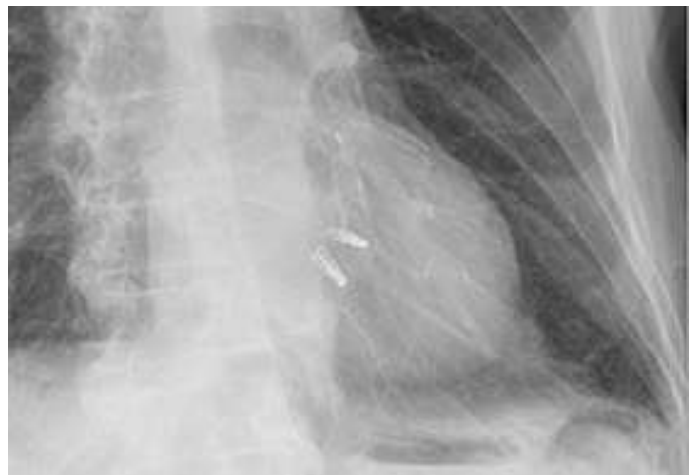

Figure 13: Appearance of MitraClip on chest x-ray

### MitraClip and the Ideal Anatomy for its Application <sup>15</sup>

- ✓ Pathology on the A2/P2 areas of the mitral valve
- ✓ Lack of multiple jets of regurgitation
- ✓ Lack of advanced congestive HF (left ventricular ejection fraction >30% )
- ✓ Lack of severe LV dilation (left ventricular end-diastolic diameter <70 mm)
- ✓ Left ventricular end-diastolic volume <200 mL)

- ✓ Etiology of mitral regurgitation not being rheumatic or radiation-induced heart disease
- ✓ Mitral valve area  $\geq 4 \text{ cm}^2$

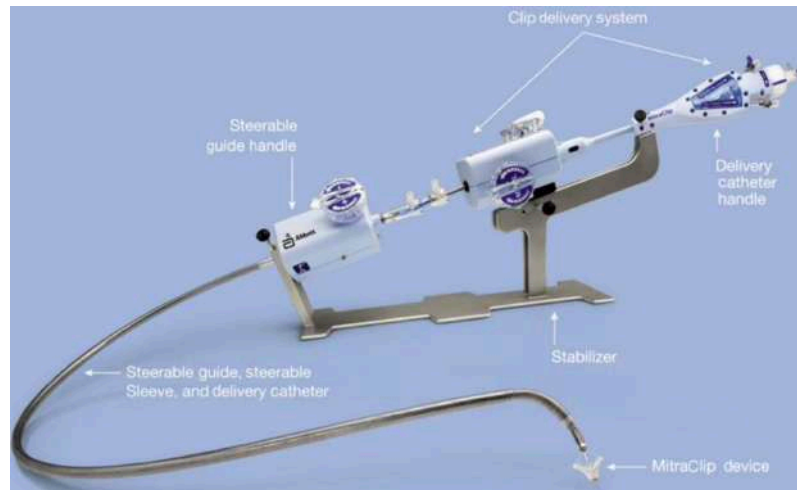


Figure 14: MitraClip system

## August 13<sup>th</sup> - Friday

### Interventional Experience: Transapical TAVI (Transcatheter Aortic Valve Implantation)

The day started with a rather different intervention. It was a joint case between Cardiac surgery and Cardiology. Both teams were in the same operating room, which gave us almost little to no space to move. The procedure was a TAVI, but the approach to the aortic valve was going to be interesting.

Before procedures like TAVI, the arteries of patients must be checked to see if they are healthy and patent to allow the passage of the aortic valve. None of the possible arterial routes were healthy in this patient, which gave the physicians no other choice but to opt for surgery, which would require an incision on the apex to insert the catheter directly through the heart wall into the aortic annulus. This is called the *transapical* approach. I was told by Dr. Rushing that this used to be the only way to replace patients' valves before the transcatheter approach was adopted.

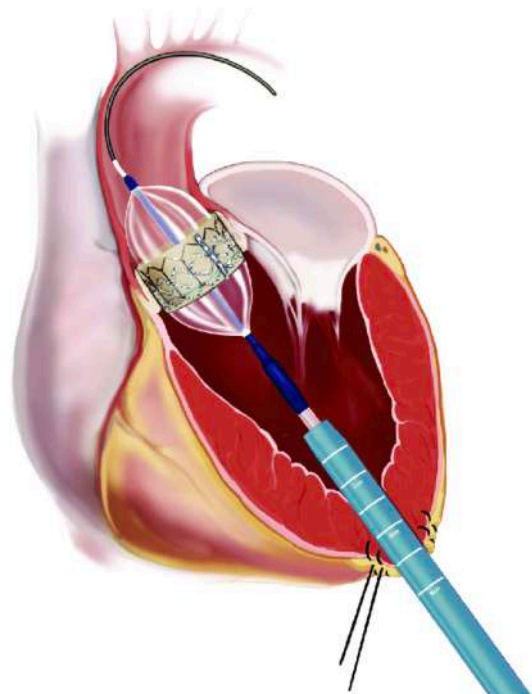


Figure 15: Transapical Valve Implantation

Dr. Pelletier was the surgeon and Dr. Attizzani was the interventional cardiologist of this case. Dr. Pelletier made the apical incision and Dr. Attizzani, along with his fellows implanted the valve. It was then followed by TEE viewing, to check if the valve was in the correct place and if there were any periannular leaks. Without any mistakes, leaks or complications, the operation was completed with success.

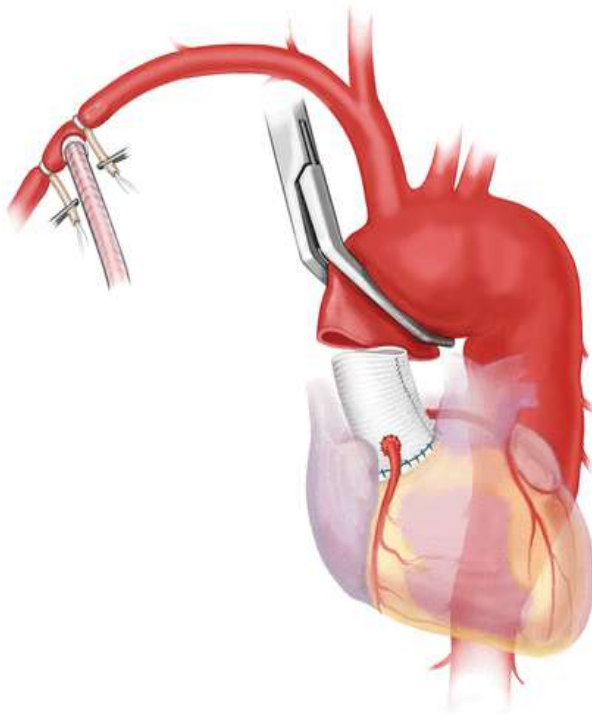
### **Surgical Experience: Biventricular Pacemaker Implantation**

I drove to UH Ahuja to join Dr. Markowitz in a biventricular pacemaker implantation operation. Although it wasn't a major one, this still required the full operating room preparation, minus cardiopulmonary bypass. Pacemakers are devices that implanted almost always percutaneously. However, this patient wasn't the case. The cardiologist who attempted to place the pacing wires onto ventricles was unable to do so, due to difficult anatomy, fat content and the weight of the patient. Therefore, it was up to a cardiac surgeon to put the wires in place through lateral thoracotomy approach. When Dr. Markowitz made the incision and proceeded to advance the wires onto epicardium, he was also having a far-from-easy time. The heart was deep, and he had to cut through many centimeters of fat to reach it. In the end, Dr. Markowitz implanted one end of the wires into the epicardium and placed the other end to the level of the left clavicle, which would enable a cardiologist to connect them to a pacemaker device later.

## **WEEK 3**

### **August 16<sup>th</sup> - Monday**

#### **Surgical Experience #1: Ascending Aorta Replacement**



*Figure 16: Ascending aorta replacement*

The new week started with a case with Dr. Markowitz at Ahuja. The patient was a 72-year-old female with a dilated ascending aorta. The dimension was 50 mm in diameter, which put the patient at risk of aortic dissection. The patient had a history of hypertension, type 2 diabetes and osteoarthritis. The aortic valve was trileaflet, so hypertension and old age seemed to be the only risks that contributed to her case.

The operation started with cannulation of the right axillary artery, which allowed the body to be perfused throughout cross-clamping of the aorta. In this type of cannulation, oxygenated blood returning from the perfusion machine enters the body through a side graft placed on the axillary artery. Then, the blood can both proceed to the right, which perfuses the right upper extremity, as well to the innominate artery and the aorta, through which the brain and the rest of the body can be perfused, while

having the heart and the ascending aorta bypassed. After axillary cannulation, bicaval cannula was placed into both venae cavae.

As the cardiopulmonary bypass was established, it was time to dissect the aorta from the sinotubular junction. Because the aortic root wasn't affected, only the ascending was going to be replaced. The aortic graft was removed from its packaging and given to Dr.

Markowitz. He first anastomosed the distal end of the graft to the aortic arch, then the proximal end to the sinotubular junction. After graft placement was complete, the patient was put off bypass to check for any leaks. The operation was a success and there were no complications.

Preserving the aortic root and not manipulating the aortic valve are what makes this operation different from David surgery.

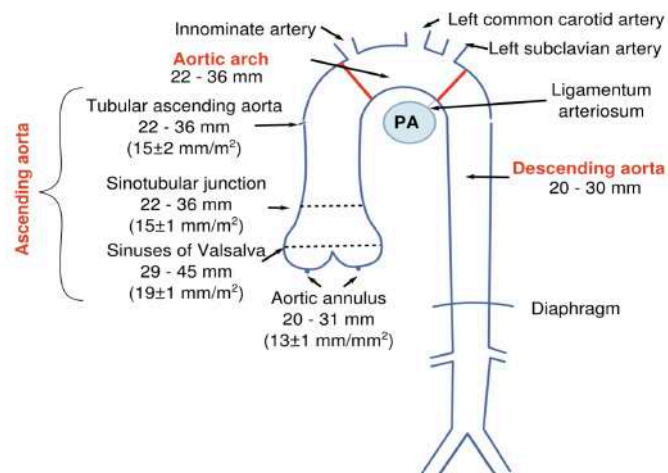


Figure 17: Normal dimensions of segments of aorta

### Clinical Experience: Outpatient Clinic

After the surgery, Dr. Markowitz and I headed downstairs to see patient at the outpatient clinic. There were four patients, two of which were follow-ups, and the remaining were referred.

The first patient was a 53-year-old female Jehovah's Witness, who had undergone mitral valve replacement five weeks ago. She was healthy and in good shape, although still fatigued from surgery. Dr. Markowitz told her there was nothing keeping her from going back to her job, as long as she felt good.

The second patient was a male in his fifties. He had been diagnosed with aortic dilation, found incidentally on CT that was performed for his diverticulitis, which was later confirmed with echocardiography. Because the diameter was 45 mm, Dr. Markowitz explained to the patient that he wasn't in need for urgent surgery and follow up with echo every 6 months and CT scan every 12 months would be the only course of action in his case.

The next patient was a 40-year-old male, who was referred for severe mitral valve regurgitation. He had no symptoms and was very fit. Annuloplasty was planned for next month, which was going to be followed by an orthopedic surgery in December.

The last patient in the outpatient clinic was an 83-year-old female, a follow up patient, who had undergone aortic valve replacement 9 years ago. Dr. Markowitz had opted for porcine valve, which was still durable.


### Surgical Experience #2: Triple Coronary Artery Bypass

The second and last surgery of the day was, yet another, coronary bypass. The patient was a 66-year-old male with obstructed LAD, Cx, and RCA. Dr. Markowitz and I looked at the angiograms together before the surgery started and talked about which grafts to procure and which coronaries to anastomose them with. Left internal mammary artery to LAD, right internal mammary artery to Cx and left radial artery to RCA was the plan. The main challenge of this operation turned out to be the proximity of and the lack of tissue in between the IMA's and the thoracic wall; the arteries were very hard to procure, and they could have been seriously severed with even a slight mistake. Cardiopulmonary bypass was established, retrograde cardioplegia was used and the arteries were anastomosed as planned.

## August 17<sup>th</sup> - Tuesday

### Echocardiography

Today was different from the others since I did not attend any surgeries at all. With the help of Dr. Markowitz, I had found myself back in the Cardiology Department to learn to read echocardiograms. Dr. Ellen Sabik, who I was told was an expert in echocardiographic imaging, kindly accepted to teach me some of the basics. The black and white images and shapes of echo, that wouldn't make any sense outside the medical world had always daunted to me. We sat in the reading room and started looking at echos of the patients after a small introduction and chatting session. Dr. Sabik first started with the views from which the images were taken. Then she identified every structure she saw. After a brief introduction to images, she started talking about the pathologies she saw. We mostly identified valvular regurgitations, chordae ruptures and myocardial contractility defects. Finally, she gave me a couple of tips to always keep in mind while performing and reading echos.



*Figure 18: Echocardiography reading room*

I also had the chance to see echos being performed. Connie, the sonographer took me with her to teach me how and where to hold the probe to get certain views.

Some notes I took from my session with Dr. Sabik:

- Edwards branded valves keep their structure as they are inflated, whereas Medtronic valves continue to expand inside the annulus over time until they reach their final dimensions. The use of a Medtronic valve would explain a finding of valvular regurgitation in a post-op patient for some time.
- The all-popular Mercedes sign, which is thought to depict a trileaflet aortic valve is actually not reliable at all! In cases of leaflets with raphes in the middle, the image of the valve can be mistaken for a trileaflet one, in spite of being only bileaflet. The correct way to determine if an aortic valve is

trileaflet, is to look at it during systole and see all the leaflets open to create a triangle.

- When viewing the left ventricle, the technique to determine if the image is adequate is looking at the apex and making sure it's not moving downwards during systole. In a correct view, only the septal and lateral walls of the left ventricle come close during contraction, while the apex stays in place.
- The inferior vena cava collapses during inspiration.
- Making measurements using orthogonal axes is of utmost importance. Not abiding to this rule will overestimate values and yield to misdiagnoses.

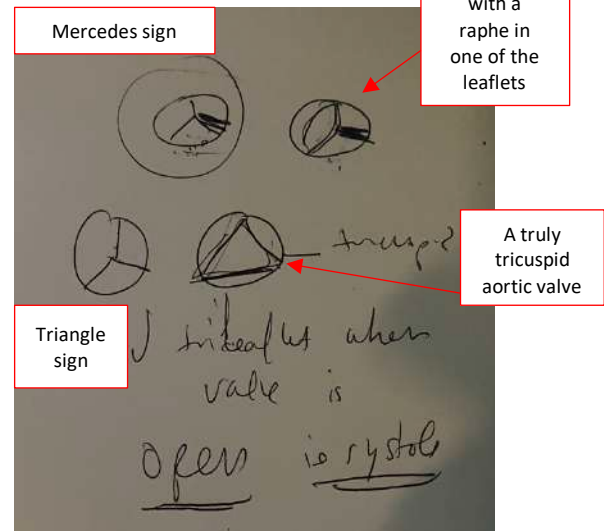


Figure 19: Dr. Sabik's explanation of the Mercedes and Triangle signs

## August 18<sup>th</sup> - Wednesday

### Surgical Experience #1: Coronary Artery Bypass and Aortic Valve Replacement

First surgery of the day I observed at was performed by Dr. Cristian Baeza, Cris's father. It was a triple coronary bypass and aortic valve replacement operation on a 76-year-old male patient. He had undergone CABG 20 years ago, but due to occlusions in margins of arteries distal to the grafts, a redo CABG became inevitable. The patient also developed aortic valve stenosis over the years, which has been decided to replace with a biological valve. The main challenge of redoing sternotomy is having to be extremely careful about not severing the heart and previously grafted arteries. The previous surgeon of this patient didn't close the pericardium, which contributed to this challenge even more. I have heard almost all cardiac surgeons here at UH that closing the pericardium after an open-heart surgery is imperative, as the pericardium creates a very protective barrier will be very useful if a redo operation is ever required in the future.

The previously bypassed artery was LIMA to LAD. In addition to an LAD lesion, occlusions in PDA and PLB developed over the years as well. In this surgery, radial artery to be anastomosed to LAD and right saphenous vein to be sequentially anastomosed to PDA, PLB and Cx, were procured. Sequential vein bypass is a type of anastomosis, where the surgeon anastomoses the graft both from the end, and the side of the graft. To achieve that, Dr. Baeza connected the distal end of the saphenous graft to PLB, created a hole on the side, 3 cm proximal to the distal end on the same graft. He also performed an end-to-side anastomosis, where he used the remaining of saphenous and used it as a branch to perfuse the Cx artery. All very complicated but yielded to amazing results in the end. He later anastomosed the radial artery to the RCA.

The final step of the operation was to replace the aortic valve. Dr. Baeza used a very particular type of replacement valve, which was made from bioprosthetic material, just like

most other valves do. What made this valve interesting was the fact that it was self-expanding, just like TAVI, and was implanted into place with the help of a balloon. Also, the sizes of the valves weren't as precise as the other valves, as this replacement only had sizes S, M and L, whereas the others were measured in millimeters. Survival rate of this type of this type of valve unknown and is to receive results in the long run.

## Surgical Experience #2: Stanford Type A (DeBakey Type II) Aortic Dissection

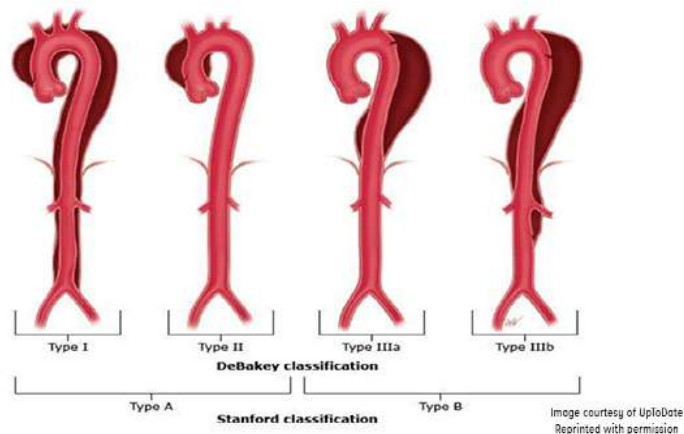


Figure 20: Stanford and DeBakey classifications of aortic dissection

During the previous operation, the patient who was being prepped for surgery due to an aortic dissection got deteriorated. The 64-year-old male patient started to develop neurological symptoms, such as slurry speech, confusion, stupor, and left-side neglect. This development resulted in the surgery being brought early by two hours; Dr. Baeza had to operate on him without giving a break in between two surgeries.

The patient had a history of hypertension, chronic kidney disease and atrial flutter, as well as abuse of schedule 2 drugs.

The dissection was categorized as Stanford class A, or DeBakey class I; dissection originating from the ascending aorta and expending all the way to the iliac arteries. The culprit of the neurologic deficits was the flap covering the innominate artery, impeding cerebral perfusion. The surgery entailed the ascending aorta and the proximal hemiarch to be replaced with grafts. Dr. Baeza cannulated the right axillary artery to maintain both systemic and cerebral blood flow, and to keep the blood from flowing through the ascending aorta, so that he could replace it. The replacement took around 30 minutes at most. The thing we had to wait the most for was heating the patient back to physiological temperature levels. As soon as the grafts were anastomosed and the temperature was back up to 36.5°C, the patient's chest was closed, and the surgery was over. The thoracic and abdominal aortas were scheduled to be replaced at a later time.

## August 19<sup>th</sup> - Thursday

### Cardiac MRI and CT

Today I got a different view of the heart. Dr. Markowitz thought it would be a good idea for me to spend time at the advanced cardiac imaging lab, to see new breakthroughs in this field. We walked to the Center for Advanced Heart and Vascular Care, where we met Dr. Sanjay Rajagopalan, who I was told was the expert in his field. We started with a little chat,

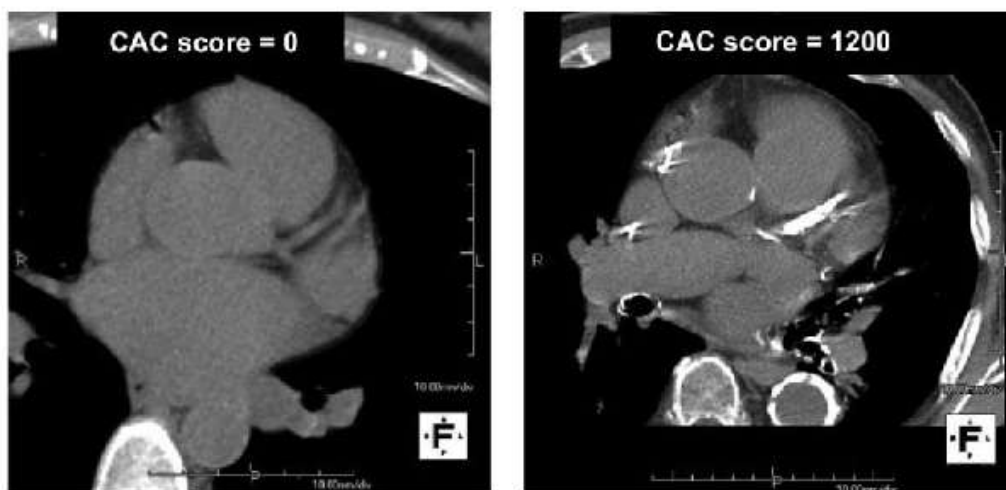
talked about this and that and then dove right into interpreting cardiac CT. Because of my previous clerkships at school, I wasn't unfamiliar with what I was seeing on the screen. Dr. Rajagopalan asked me to identify several structures, and I got most of them right. Then he explained to me what he was particularly looking at on cardiac CT images. He was mostly interested in the coronary arteries, dimensions of the segments of the aorta, congenital defects, sizes of the chambers, wall thicknesses and more. He also took the time to talk about the Glagovian remodeling when he saw a resembling finding. It is the compensatory dilatation of the artery, in which the atherosclerotic plaque grows away from the vascular lumen and consequently blood flow through the artery is less limited, compared to the regular form of vascular occlusion.

We then looked at a few MR images. This part of my time in the imaging lab was less clear to me, as it was my first attempt at looking and trying to decipher cardiac MRI. From what I observed, it can be used to precisely assess myocardial viability and function, detection of infarcts, valvular diseases and their degrees of severity, even by looking at the blood flow through the chambers.

During the rest of my time in the advanced imaging lab, Dr. Rajagopalan looked at coronary artery calcium scores. It was a relatively easier imaging technique to comprehend. I had heard about the calcium scoring when I attended the TAVR meeting last Monday but had very little idea about what it actually was and how it was calculated.

Dr. Rajagopalan had to leave for a meeting at 4 pm. I thanked him for a truly enlightening experience and took off.

### Coronary Artery Calcium Scoring <sup>16</sup>



*Figure 21: CT showing calcified plaques in coronary arteries*

One of the most important associations in atherosclerotic vascular diseases is the presence of vascular calcification. This association has enabled imaging specialists to detect atherosclerotic cardiovascular diseases (ASCVD) in stages which patients are asymptomatic.

CAC scan is acquired through the use of multi-detector, non-contrast CT of the heart. The areas with calcium density are quantified by the presence of calcified atherosclerosis at least 1 mm<sup>2</sup> with a density of >130 Hounsfield units and multiplication by density weighting factor; this is called the Agatston method.

The patient does not need any preparation before the scan; no prior hunger or medication use is required.

It is important to know which section of the population should undergo calcium scoring, as not every asymptomatic patient is indicated for one.

Measurement of CAC suggested for:

- Asymptomatic adults >40 years at intermediate risk (7.5-9.9% 10-year risk),
- Adults with borderline elevated ASCVD risk (5.0-7.4% 10-year risk) with family history of premature ASCVD.

Measurement of CAC recommended against:

- Patients with low ASCVD risk (<5% 10-year risk),
- Patients presenting with myocardial ischemic symptoms,
- Patients with low (<5% 10-year risk) or high (>20% 10-year risk).

Results of the CAC scoring can be interpreted as follows:

Table 4: Severity of Coronary Artery Disease Based on Calcium Score

0 Agatston units	No identifiable disease
1-99 Agatston units	Mild disease
100-399 Agatston units	Moderate disease
>400 Agatston units	Severe disease

Presence and severity of coronary artery calcium has been used as a trigger for initiation of preventive medical therapies, such as aspirin, statins, anti-hypertensive drugs, and even exercise. Patients with CAC>100 have been found to benefit from statin therapy. Adult patients younger than 70 years with CAC>100 have been found to benefit from aspirin use.

## August 20<sup>th</sup> – Friday

### The Watchman Device

To everybody's surprise, there were no cardiac surgeries scheduled for today. This turned out to be an opportunity for me to see an intervention at the Cath lab, which I hadn't heard before: the Watchman procedure. Dr. Steven Filby, an interventional cardiologist was waiting for me there.

The Watchman implant is a recently-FDA-approved apparatus, constructed from nitinol mesh and stabilizing wires, that occludes the left atrial appendage when placed. The rationale behind this procedure is occluding the ostium of the LA appendage, where most thrombi form in AFib. The first step therapy for patients with AFib is anticoagulation. However, patients who fail to comply with, have contraindications against anticoagulation therapy, recurrently bleed, or those with high falling risks can greatly benefit from LA appendage occlusion. By getting rid of the LA appendage, the risk of thrombi formation, systemic embolism, and cerebrovascular accidents are greatly reduced.




Figure 22: The Watchman device

The Watchman device requires a percutaneous approach. The device is inserted from the femoral vein, advanced through the IVC until it reaches the RA. Next, the atrial septum is transected for the device to ultimately reach the LA. Using echo and X-ray at the same time, the correct location of LA appendage ostium is determined. The Watchman device is inserted into the LA appendage, and slowly placed by expanding it by pushing it forward. The part with the mesh should face the LA lumen, whereas the parts with the stabilizing wires stay in the appendage. The mesh contains substances that promote tissue growth that induces the cells to form a granulation tissue over the device, and form a smooth LA endocardial tissue, which seals off the LA appendage indefinitely.

### **Interventional Experience: Watchman Procedure <sup>17</sup>**

There were two patients scheduled to undergo the Watchman procedure. The first one was 81-year-old male with paroxysmal AFib. His history revealed long-term use of apixaban and aspirin until he had to be weaned off due to colitis and rectal bleeding. The patient stated reluctance to anticoagulant use, in spite of high risk of cerebrovascular accidents. LA appendage occlusion was found to be a suitable treatment option. Halfway into the intervention just before the septal transection, due to a discovery of cystic-like formation in the interatrial septum, it was deemed dangerous to advance with the procedure and the Watchman procedure was aborted.



*Figure 23: Me, attempting to seal the LA appendage on the demo kit*

Second patient to undergo Watchman procedure was a 55-year-old man with AFib. His CHA<sub>2</sub>DS<sub>2</sub>-VASc score was 5. The patient had a history COPD, diastolic heart failure, hypertension, and TIA. Due to esophageal variceal bleeding as a result of cirrhosis, and severe thrombocytopenia, anticoagulation therapy was contraindicated. His history made this patient an excellent candidate for the Watchman device. Unlike the first patient, there were no anatomical problems along the way, and everything went smoothly.

After the procedures, the representative from Boston Scientific, the manufacturer of the Watchman device, brought a demo kit made from acrylic for the fellows and me to attempt to seal the LA appendage on a model.

August 23<sup>rd</sup> - Monday

### Surgical Ablation to Prevent Recurrent Atrial Fibrillation (Maze Procedure) <sup>18</sup>

Atrial fibrillation (AFib) is the most common type of arrhythmia in the world. It is associated with increased risk of thrombi formation, stroke, systemic emboli, heart failure and death. In patients with recurrent AFib, surgical ablation can be a treatment of choice, of which Maze procedure is an option.

The procedure entails formation of a pattern of linear scars created by incision or ablation, which consequently creates a maze of functional myocardium within the atrium that reduces the likelihood of electrical reentry waves.

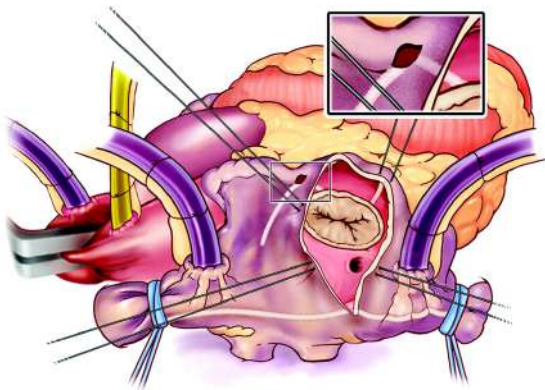


Figure 24: Maze lesions in the RA

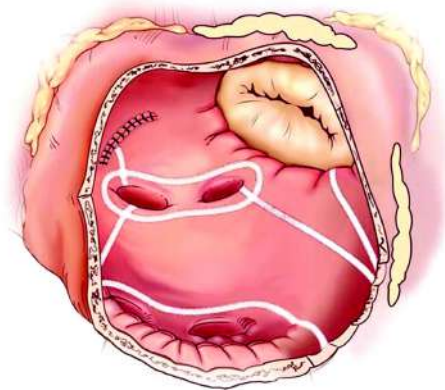


Figure 25: Maze lesions in the LA

There are different approaches in the Maze procedure, most popular being the traditional approach (Maze IV):

- Lines of ablation are created in the RA, from the SVC to the IVC and connected to the tricuspid annulus, using RF or cryothermal energy devices.
- In the LA, posterior wall, which contains the pulmonary veins is isolated in a box, which is then connected to the mitral annulus.
- In one center, this procedure was reported to cure AFib, restore AV synchrony and preserve atrial function in 98.7% of the patients. Post-op atrial pacemakers due to preoperative or iatrogenic SA node injury was required in 40% of the patients.

### Checking Up on Post-Op Patients in the ICU

Cris and I went up to the 3<sup>rd</sup> floor to check up on post-op patients in the cardiothoracic ICU. There, we found CNP Kehllee, who walked around with us and gave us some key points on what to monitor and what to especially keep a close eye on.

3 questions to ask when seeing a patient:

1. Are they awake? – Assessing consciousness
2. Are they urinating? – Monitoring urinary output to assess renal function.
3. Are they bleeding? – Monitoring the amount of bleeding, its consequence on blood levels (anemia?) and mental status.

3 things to check:

1. Check the scar – Is the scar intact or is it opening? Any oozing pus or other signs of inflammation?
2. Check the tube – How is the chest tube output? Is the amount increasing or decreasing?
  - a. An ideal chest tube output is <50 mL/h, but not close to 0.
  - b. If the output is close to 50 mL/h, keep a close eye on it.
  - c. 75 mL/h should raise eyebrows and one must be extra carefully monitoring, but still nothing to be alarmed about.
  - d. More than 100 mL/h requires notifying the surgeon. May indicate platelet dysfunction.
  - e. If the output is less than 30 mL/h for three consecutive hours, the tube can be pulled.
3. Check the urinary catheter – Again, monitor the UOP.

After the patient is first brought to the ICU, blood gas is sampled every thirty minutes, while biochemistry panel is checked every hour in the first 24 hours. They are later repeated less frequently.

Chest x-ray is important. First one is obtained in the first hour after the patient's arrival. Effusion in the first few x-rays is normal, mediastinum widening is expected. It is then repeated a few more times before the patient is out of the ICU.

Maintain the blood pressure at steady levels. Especially in aortic surgical patients, try to keep the BP low, but it also depends on the surgeon; but the ideal MAP is 70-80.

If the patient is hemodynamically stable, not bleeding, chest x-ray looks normal and blood gas parameters are within range, extubation is the next step.

## August 24<sup>th</sup> - Tuesday

### **Surgical Experience: Coronary Artery Bypass, Aortic Valve and Annuloplasty Ring Implantation and Repair**

The only surgery today I got to see was a special case. Firstly, it was a combination of three different procedures. Secondly, it was going to be Dr. Markowitz's fourth time implanting an HAART annuloplasty ring. Thirdly, it was my last time watching Dr. Markowitz operate on a patient during my time in Cleveland.

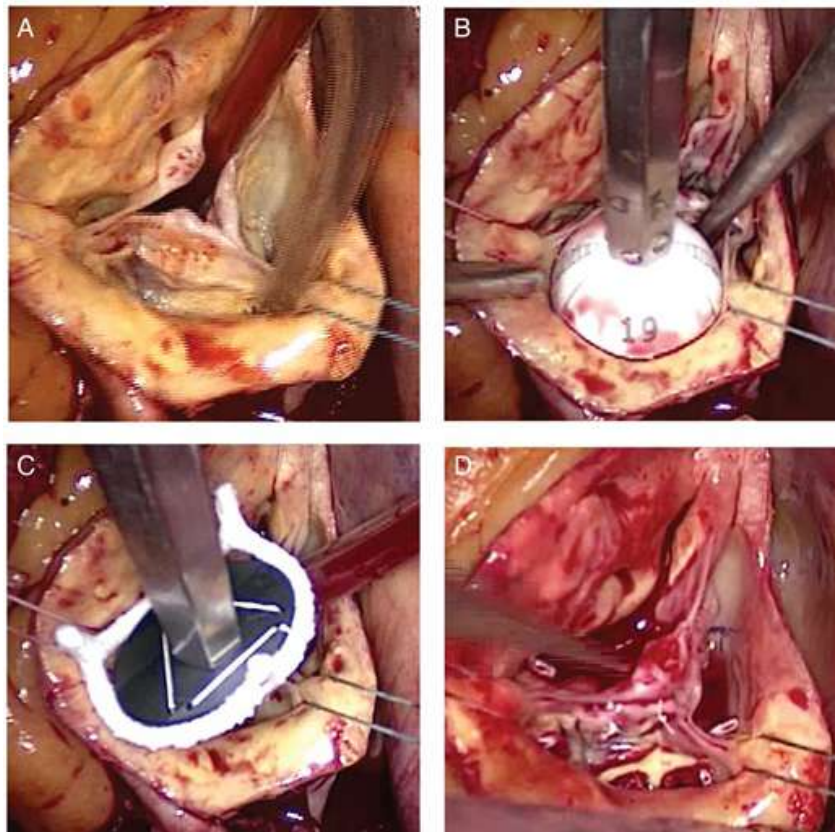
The patient was a 65-year-old male with severe aortic regurgitation, coronary artery disease, and hypertension. His history also revealed prior prostate cancer and radiation.



*Figure 26: Dr. Markowitz and I, after a successful operation*

Before Dr. Markowitz and I entered the room, the LIMA and the left radial artery were procured by Dr. Rushing. As with almost all cardiac operations, Dr. Markowitz started with initiating the cardiopulmonary bypass and placing the cardioplegia cannula: bicaval cannula into the venae cavae, the arterial cannula into the aorta and the cardioplegia cannula into the coronary sinus. Then, he began with the first part of the operation: CABG. First anastomosis was initially planned to be LIMA to LAD. However, after checking the angiograms once more, it was decided that the ramus intermedius was the obstructed artery, and the surgeons proceeded with this finding. In the end, the anastomosis was LIMA to RI. Then, the surgeons connected the left radial graft to the circumflex but waited for the aortic anastomosis until the end. It was time for the second part of the operation. For this part Dr. Scott Rankin, the inventor of the ring, connected through facetime to proctor the operation. He watched every step of the implantation and was very verbal about every correct and incorrect move the surgeons made. In the end, the HAART annuloplasty ring was placed into the subcommisural space. The ring constricted the annulus to bring the aortic leaflets closer to eliminate regurgitation. The third part of the operation was to repair the non-coronary leaflet of the aortic valve. With sutures placed in nodule and the lunules, Dr. Markowitz shaped the non-coronary leaflet, that when all three cusps of the aortic valve closed, they coapted in perfect alignment and there was no leakage when they were tested with water. At the end of the surgery, the aortic valve was visualized with TEE to check for its structure and improvement or persistence of regurgitation. Dr. Fitzgerald, the anesthesiologist of the operation, and Dr. Markowitz had a disagreement on the degree of the aortic valve gradient, which they later agreed that it was normal.

#### **HAART Annuloplasty Ring <sup>19, 20</sup>**



*Figure 27: Annuloplasty Ring Placement*

HAART annuloplasty ring is a new device that is used to reduce the size of the aortic valve annulus in cases of aortic regurgitation. The device received clearance from FDA in September 2020. The basis of the ring comes from long-term mathematical analyses of the size, shape, movement, and expansion of aortic annuli in normal population using CT angiograms. These scans revealed that the aortic annuli are elliptical in shape, having three equidistant 10° outwardly flaring sub-commissural posts. The expansion of the annuli during systole is 4%. In light of these results, the ring was developed to have an elliptical shape and with few capacity for expansion.

By implanting the HAART ring into the sub-commissure, the annulus' diameter and circumference is reduced, creating an aortic annulus size close to the physiological levels.

The advantages of ring annuloplasty over aortic valve replacement are, it doesn't require lifelong use of anticoagulants after operation, as no procoagulant structure, like a mechanical valve, is placed, and the sparing of the patient's valvular tissue.

According to a research article, 3 patients out of 65, who died within 3-year follow-up, had normal documented aortic valve function, meaning no cases of death is associated with the annuloplasty ring. Other deaths in the same trial were also unrelated with the ring annuloplasty. 7 patients required re-operative AVR in the same period of time. The authors of the article attributed all the repair failures to technical inaccuracies, further emphasizing on the safety of the ring.

## August 25<sup>th</sup> - Wednesday

### **Surgical Experience: Aortic Valve Replacement**

The surgery of today was an aortic valve replacement. The patient was a 67-year-old female patient with severe aortic stenosis. Surgeon was Dr. Hussian, assisted by Dr. Abu Omar. After the classic sequence of first incision, sternotomy, cauterization of small leaky blood vessels, initiation of cardiopulmonary bypass and cardioplegia cannula placement, the aorta was dissected to reveal the aortic valve. This dissection revealed a severely calcified, stenotic valve with very little orifice. The degree of calcification left no other option but replace the valve. Dr. Hussian opted for a bioprosthetic valve. After a quick replacement, the aorta was sutured back to its normal anatomy, and TEE was used to check the valve for regurgitations, which there weren't any. The new valve was healthy, the patient was hemodynamically stable and was subsequently closed.

### **Aortic Stenosis: Clinical Manifestations, Diagnosis, and Indications for Valve Replacement**

21, 22, 23, 24

Aortic stenosis (AS) is the narrowing of the aortic valve, causing obstruction in the outflow of the left ventricle. There are three main causes of aortic stenosis: degenerative, rheumatic, and congenitally bicuspid valve with superimposed calcification.

Degenerative AS is mostly seen in people around 70-80 years of age. Rheumatic valve disease is a result of untreated acute rheumatic fever in younger patients, which is characterized by commissural fusions and small central orifice. It is the most common cause of AS in the world, mainly affecting developing and underdeveloped nations. Bicuspid valve is a congenital heart disease with a prevalence of 1% in the general population. It has strong genetic component, which indicates first-degree relatives to be screened. It is the more common etiology of AS in developed countries. While bicuspid aortic valve may be isolated, it

can also be a component of genetic diseases, like Loeys-Dietz syndrome (2.5-17%), familial thoracic aorta syndrome (3%), and Turner syndrome (30%).

Rare causes of AS are metabolic diseases, SLE, alkaptonuria. Those with ESKD and Paget's disease have more rapid progression of aortic calcification.

The main effect of AS on the heart is left ventricle is pressure overload, which gives rise to concentric hypertrophy. The classical manifestations of AS are angina, syncope, and dyspnea on exertion. Presence of these symptoms, as mild as they may feel, are very important, as they are indicative of poor survival rates and high risk of sudden cardiac death without intervention. Survival expectancies for the symptoms are, five, three and two years respectively.

- Angina: Increase in myocardial mass causes increase in LV oxygen demand. Due to reduced expulsion of blood from the LV, the coronary blood flow is reduced and therefore the heart cannot further keep up with its increased demand. Additionally, increased LV diastolic pressure reduces perfusion pressure gradient in myocardium.
- Syncope: Exercise-induced vasodilation and simultaneous obstruction with fixed cardiac output (CO) results in hypotension and subsequently decreased cerebral perfusion.
- Dyspnea: Most common symptoms of AS. Indicative of heart failure.

One of the most important findings revealed with physical examination in mid-to-late systolic murmur in the right 2<sup>nd</sup> intercostal space. The earlier the murmur peaks, the less severe the stenosis is. Low volume and slow-rising carotid pulse are also an important finding. *Pulsus parvus et tardus* is the term, denoting a weak and late pulse in the carotid, which is characteristic of AS. Diagnosis is made with echocardiography.

Three main parameters for grading the severity of AS checked on echo are AV area, mean AV gradient and AV maximum velocity.

Table 5: Severity of AS Based on Echocardiographic Findings

	Mild	Moderate	Severe
<b>AV area</b>	1.5-2.0 cm <sup>2</sup>	1.0-1.5 cm <sup>2</sup>	<1.0 cm <sup>2</sup>
<b>Mean AV gradient</b>	<25 mmHg	25-40 mmHg	>40 mmHg
<b>AV Vmax</b>	<2.9 m/s	3.0-3.9 m/s	>4 m/s

There are two types of interventions for the treatment of AS: surgical replacement of the aortic valve, and transcatheter aortic valve implantation (TAVI). For indications for intervention in AS, two parameters are looked for respectively: presence of severe AS and presence of symptoms. Severe AS is identified by Vmax >4 m/s, mean gradient >40 m/s and area <1.0 cm<sup>2</sup>.

Surgical aortic valve repair should be put in first place in symptomatic patients. In those with symptoms but are inoperable or with advanced ages should be advanced with medical therapy, which consists of beta blockers and diuretics. In asymptomatic patients, the next parameter to check is the EF. EF<50% necessitates surgical replacement. Additionally, patients with severe high gradient AS, who are undergoing cardiac surgery, those with low surgical risk (STS score <4%) and decreased exercise tolerance are candidates for surgical aortic valve replacement.

In patients with high surgery risks (STS score >4%), advanced ages, history of cardiac surgery, presence of coronary bypass grafts that may be severed with sternotomy, porcelain aorta and favorable access for transfemoral TAVI, are candidates for TAVI.

Approximately one half of the patients with AS have underlying coronary artery disease. Therefore, performing coronary angiography prior to surgery, which is indicated before valve intervention, may reveal coronary arteries in need of coronary bypass grafting. Patients who are candidates for CABG can have both diseases corrected at the same surgery.

## August 26<sup>th</sup> – Thursday

### Surgical Experience: Left Ventricular Assist Device (LVAD) Placement

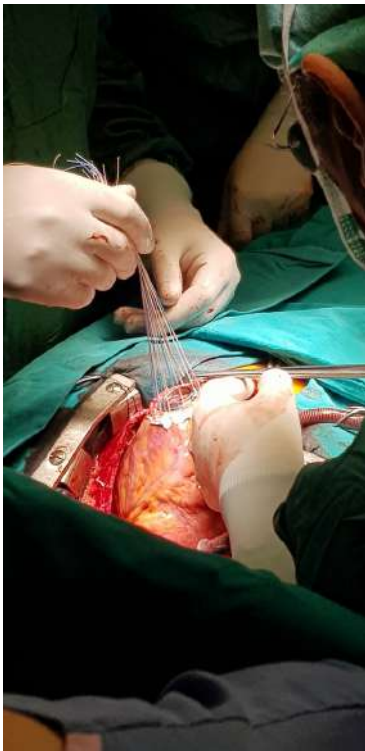


Figure 28: Placement of the ring, where LVAD will be inserted into

Today's surgery was different from the ones I have seen so far. The patient was a 48-year-old female with heart failure with reduced ejection fraction of 20%. Her history revealed many comorbidities, including hypertension, diabetes, COPD, non-ischemic cardiomyopathy, obstructive sleep apnea, scleroderma, and hypothyroidism.

Because medical therapy wasn't enough for this patient, it was decided that she should have left ventricular assist device placed, while a decision about heart transplantation candidacy was being made.

The surgeon was Dr. Abu-Omar with Dr. Elgudin assisting him. In order to place the LVAD, a metal ring had to be fixated on the cannulation site on the external wall of the apex. With the ring in place, a punch was used to create a hole on the heart and the inflow conduit of the device was inserted into that site; through that conduit, the blood would be taken up by the device. The outflow graft was then anastomosed to the ascending aorta; this is the tract through which the blood would return to the circulation. The final step was to set the impeller to optimal spin rate and blood flow. Because the tip of the cable that connected the device to the battery was bent, a new one had to be found. After that, Dr. Abu-Omar set the device to ideal setting for the patient and ended the procedure.

### Left Ventricular Assist Devices (LVAD) and their Clinical Use <sup>25</sup>

LVADs are devices that provide mechanical support in circulation of the patients with heart failures with reduced ejection fraction (HFrEF). These devices are important for patients with decompensating HF, who do not benefit from medical therapy or await heart transplantation.

There are three different uses and indications for LVADs: bridge to transplantation, bridge to decision, and destination therapy.

- Bridge to transplantation is defined by the implantation of LVAD into a patient while they await an organ to be available for transplantation. These patients have advanced HF (NYHA class IIIb or IV) with deteriorating status and cannot survive without circulatory support.

- Bridge to decision is a term that defines patients who receive LVADs until a decision has been made regarding transplantation eligibility. This status is important in those who have reversible contraindications to transplant operations, such as an end-organ dysfunction.
- Destination therapy means the LVAD is implanted to stay in the patient permanently, as an alternative to transplantation. These patients have end-stage HF but are ineligible for cardiac transplantation.

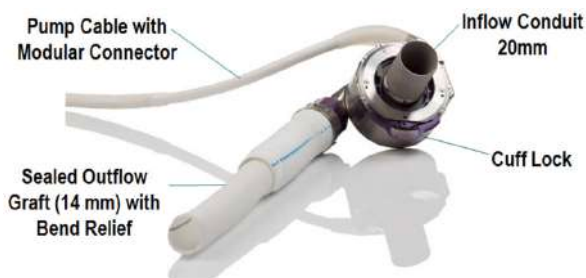

Figure 29: HeartMate 3 LVAD pump

Other indications for LVADs are as follows:

- Only FDA approved devices can be used, in device-approved facilities.
- The patient must have a life expectancy of less than two years.
- The patient must have NYHA class IV CHF and should fail to respond to medical therapy consisting of beta blockers and ACEI for at least 45 out of 60 days.
- LVEF should be less than 25%

## ○ August 27<sup>th</sup> - Friday

### **Surgical Experience: Ascending and Hemiarch Aorta Replacement and Debranching**

Today's surgery was one of the most intricate operations I have ever seen. Dr. Baeza operated on a 67-year-old male with ascending and thoracic aortic aneurysm and an aortic ulcer between the left common carotid (LCC) and left subclavian arteries (LSA). The H and P of the patient revealed that he also suffers from cardiomyopathy, hypertension, benign prostatic hyperplasia and chronic hepatitis C. Mild levels of MR and TR had been also detected on echo, and other valves were deemed healthy.

This surgery was replacement of the ascending and hemiarch aorta and debranching of the innominate and LSC arteries from the aortic arch. Left common carotid artery (LCC) was going to be left intact in this operation because of its suboptimal location, considering its relation to the recurrent laryngeal nerve. Dr. Baeza told me that this operation was considered as a bridge to TEVAR, which was planned for some time next week.



Figure 30: Dr. Baeza and I in the OR

Dr. Baeza debranched the two arteries. Then, he dissected the aorta above the sinotubular junction (STJ) and right before the branching point of LCC and replaced it with Dacron graft. He then brought a bifurcating graft. The side with the two branches were end-to-end anastomosed with the arteries, while the unified end of the graft was end-to-side anastomosed to the aorta, right above the STJ.

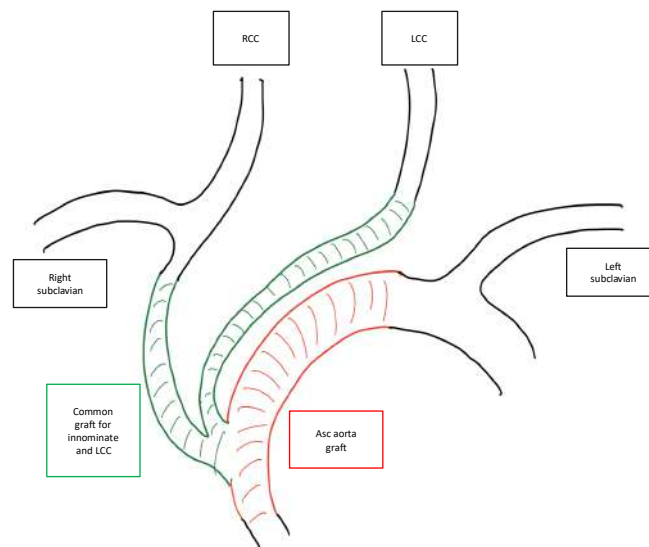


Figure 31: Depiction of the end-result of the operation

**WEEK 5**

**August 30<sup>th</sup> - Monday**

### Surgical Experience: ECMO Discontinuation

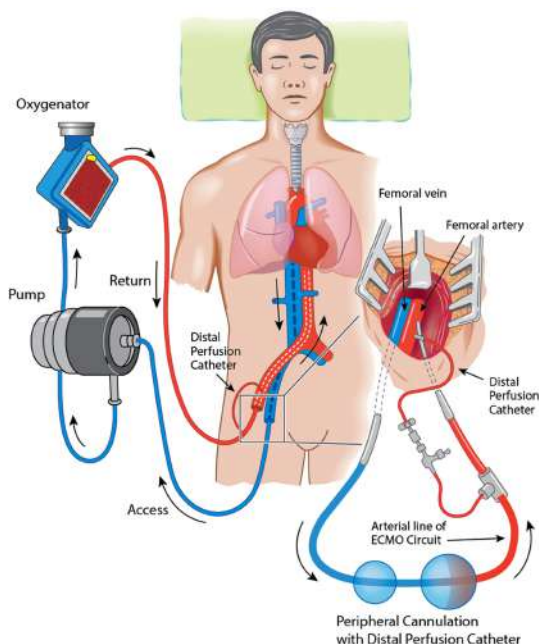


Figure 32: ECMO catheter placement

The only surgery I got to see was a relatively minor one, compared to other cases I had seen before: it was an ECMO discontinuation. When I got a closer look at the patient's face and checked the board for his identity and history, I recognized him right away. He was the patient who had had a cardiac arrest early last week, after a triple coronary bypass operation. The staff in the ICU had to resuscitate him for an hour before he was connected to an ECMO machine, had a more stable rhythm and hemodynamics and taken down to the OR. It was later revealed that he had a cardiac tamponade. Dr. Elgudin slowly and steadily removed the arterial and venous catheters of the ECMO, then meticulously fixed the femoral vessels where the catheters had to be placed.

### Clinical Experience: TAVR Clinic

To attend my last TAVR clinic, I took the stairs to go down one floor and walk to Mather 1800. Dr. Pelletier and Dr. Attizzani were seeing new and follow up patients together.

First patient I got to see was an interesting case of aortic stenosis. The degree of AS was severe, even though Vmax was between 2.0-3.0 and the gradient was 28 mmHg, which wouldn't normally put the patient in a class of severe AS. Dr. Pelletier explained to me, that when the heart cannot contract forcefully and the EF is low, the parameters could be falsely interpreted as AS with lower severity. Dobutamine stress test would be the appropriate next step to correctly measure the necessary parameters.

The second patient was also in the exact situation as the first one.

The third patient was a female in her fifties, undergoing chemotherapy and radiotherapy for glioblastoma multiforme. We were told that she got diagnosed with it after being pulled over by the police due to erratic driving, which was followed by a trip to the hospital and a subsequent MRI. The patient also suffered from AS, but the TAVR team decided to touch base with her oncologist and neurosurgeon to discuss her state and learn the prognosis of her tumor before proceeding with any step.

The last patient was talked to on a video call. The male patient in his seventies, who smoke two packs a day, had concomitant mitral and tricuspid insufficiencies. The TAVR team decided to choose the suitable intervention for this patient after he will undergo some tests and follow ups in the coming days.

### New York Heart Association Classification of Cardiovascular Disability

Class	Table 7: Functional Classification of Cardiovascular Disability
I	Patients with cardiac disease but without resulting limitations of physical activity. Ordinary physical activity does not cause undue fatigue, palpitation, dyspnea, or anginal pain.
II	Patients with cardiac disease resulting in slight limitation of physical activity. They are comfortable at rest. Ordinary physical activity results in fatigue, palpitation, dyspnea, or anginal pain.
III	Patients with cardiac disease resulting in marked limitation of physical activity. They are comfortable at rest. Less-than-ordinary physical activity causes fatigue, palpitation, dyspnea, or anginal pain.
IV	Patients with cardiac disease resulting in inability to carry on any physical activity without discomfort. Symptoms of cardiac insufficiency or of the anginal syndrome may be present even at rest. If any physical activity is undertaken, discomfort is increased.

## Mitral Stenosis<sup>26, 27, 28, 29, 30, 31, 32</sup>

Mitral stenosis (MS) is the narrowing of the mitral valve, obstructing blood flow from the left atrium to the left ventricle. While it may initially seem like it's a problem limited to the left heart, its ultimate effects are exerted on the lungs and the right heart. As the left atrium fails to pump blood through a narrow the mitral valve, the pressure in the chamber subsequently increases, and so does the pressure in the lungs and the right heart, respectively, over time. The almost exclusive cause of MS is rheumatic heart disease, followed by a small percentage of mitral annular calcification. Other causes are radiation exposure or radiotherapy, congenital causes, and rare metabolic and rheumatologic conditions. The clinical manifestations and treatments vary by the etiology.

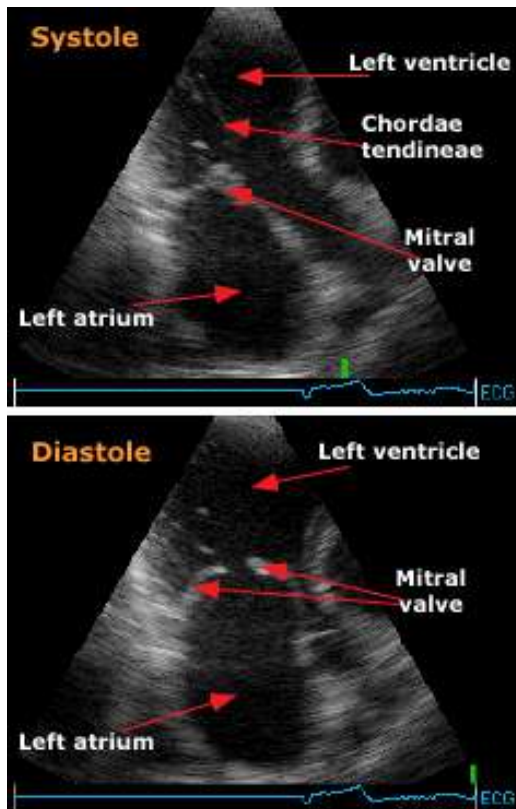


Figure 33: Thickening, mobility limitation and doming of mitral leaflets

Rheumatic heart disease (RHD) is a condition more commonly seen in developing and less-developed countries. It is the result of acute rheumatic fever (ARF). ARF classically occurs 2 weeks after pharyngeal, or 3 weeks after skin infection with group A beta hemolytic streptococcal infection (*S. pyogenes*), causing *pancarditis*. The problem arises from tissue injury caused by immune-mediated response stimulated via molecular mimicry. The similarities between the structure of *S. pyogenes* and the proteins on of cell in the mitral valve tissue direct the immune cells to falsely secrete antibodies directed against the human proteins. Tiny nodules form on the valve leaflets, and cause them to thicken, fibrose, fuse at coaptation sites, and shorten chordae. These nodules lack infection. Progression to MS does not happen in a short period of time; RHD is initially characterized MR and followed by MS over time. At least 65% of patients with a single episode of rheumatic fever progress to RHD with demonstrable valvular disease. Of the remaining 35% of patients, 44% of them develop signs of valvular disease over a course of 20 years. Patients

with rheumatic MS usually present with exertional dyspnea, and less commonly hemoptysis, chest pain, ascites, which are the results of pulmonary hypertension and right heart failure. Further manifestations include thromboembolic events due to AFib and hoarseness (Ortner's syndrome), which point out to left atrial enlargement. Classic cardiac auscultatory findings are presystolic accentuation, sharp S1, opening snap (due to abrupt halt in the movement of the mitral leaflets) and diastolic murmur – this tetralogy is called the 'Duroziez rhythm'. Electrocardiogram may reveal AFib and p mitrale (wide and bifid P wave).

Mitral annular calcification (MAC) is the calcium deposition along and beneath the mitral valve annulus, while the commissures and leaflets are spared. Its exact pathophysiology is still unclear, but it is thought to be a result of endothelial disruption and accumulation of oxidized lipids in these disrupted sites. The lipids stimulate T lymphocytes, macrophages, and mast cells to activate extracellular matrix remodeling. Presence of connective tissue disorders, Marfan's syndrome, chronic inflammatory systemic contribute to earlier development of MAC. Arrhythmias, such as AFib, AVB, BBB and bradyarrhythmias are also associated with MAC. Aortic sclerosis is another condition associated. Prevalence of mitral calcification without obstruction 3-9% among the population of 50-60 years.

Diagnosis of MS is made with echocardiography. Commissural fusion resulting in diastolic doming with leaflet tips pointing towards each other is a pathognomonic finding for rheumatic mitral disease. The valve orifice area should be narrow. Left atrium and chambers of the right heart may be dilated, depending on the progression and duration of the disease. MAC, on the other hand is identified by the presence of hyperdense, irregular structures on the annulus.

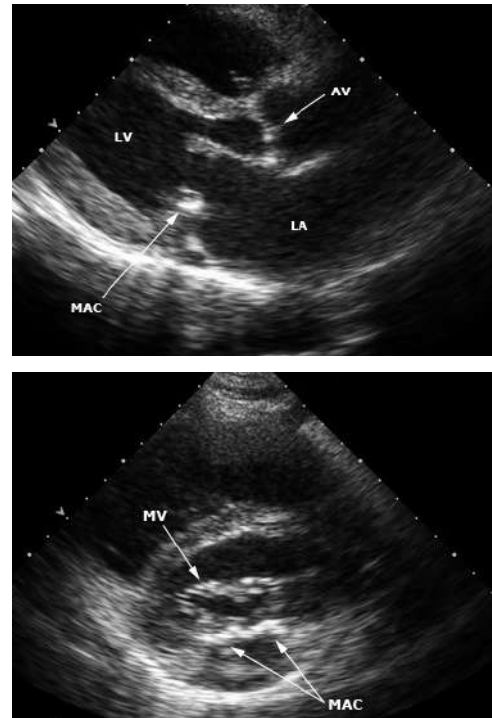


Figure 34: a) MAC, PLA view b) MAC, PSA view

Table 6: Severity of MS Based on Echocardiographic Findings

	Mild	Moderate	Severe
<b>MAC involvement</b>	<1/3 of annulus	1/3-2/3 of annulus	>1/3 of annulus
<b>MV area (MVA)</b>	2.0-1.6 cm <sup>2</sup>	1.5-1.0 cm <sup>2</sup>	<1.0 cm <sup>2</sup>
<b>Mean MV gradient</b>	<5 mmHg	5-10 mmHg	>10 mmHg
<b>Pressure half-time (PHT)</b>	<140 ms	140-220 ms	>220 ms
<b>Pulmonary artery systolic pressure</b>	<30 mmHg	30-50 mmHg	>50 mmHg

Patients with history of ARF are recommended to take prophylaxis to prevent rheumatic heart disease: 3-4-weekly injections of intramuscular benzathine penicillin for 10 years, or until the age of 40, whichever is longer.

Treatment options for MS are very diverse, both in terms of surgery and cardiologic intervention. Medical management also plays an important role.

Patients with MS require anticoagulation to prevent thromboembolism. Warfarin, heparin or direct thrombin inhibitors are amenable choices. Non-vitamin K oral anticoagulants (NOAK) are not to be prescribed.

Mitral valve replacement surgery entails the use of either mechanical or bioprosthetic valve to replace the native mitral valve of the patient. Open mitral valve commissurotomy is splitting the commissures surgically, which requires open sternotomy and CPB.

Percutaneous mitral balloon valvotomy (PMBV), on the other hand, is a minimally invasive

intervention that requires much shorter hospital stay. A deflated balloon is inserted into the femoral vein, advanced to the LA through transseptal puncture and placed across the mitral valve. Rapid inflation and deflation of the balloon separates the fused commissures.

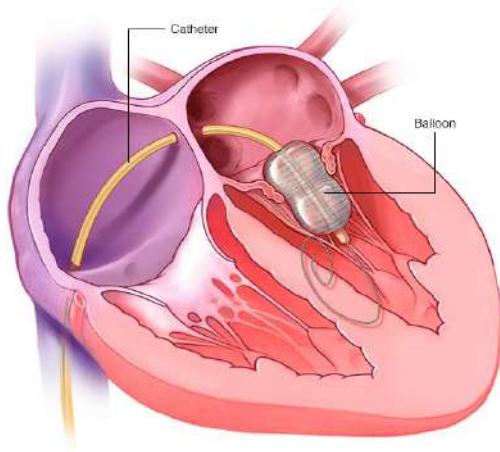


Figure 35: Percutaneous balloon mitral valvotomy

Percutaneous mitral balloon valvotomy for symptomatic patients with  $MVA < 1.5 \text{ cm}^2$  with favorable valve morphology, absence of LA thrombus and absence of moderate/severe MR. PMBV is preferred in cases with rheumatic MS; use in MAC is not suitable and there is not enough data on cases with congenital MS. Indications for intervention are as follows:

- Percutaneous mitral balloon valvotomy for symptomatic patients with  $MVA < 1.5 \text{ cm}^2$  with favorable valve morphology, absence of LA thrombus and absence of moderate/severe MR.
- Mitral valve surgery in symptomatic patients with  $MVA < 1.5 \text{ cm}^2$  who are not high risk for surgery, already undergoing cardiac surgery for other pathology or patients who are not candidates for valvotomy
- Percutaneous mitral balloon valvotomy for asymptomatic patients with  $MVA < 1.0 \text{ cm}^2$  with favorable valve morphology, absence of LA thrombus and absence of moderate/severe MR.

## August 31<sup>st</sup> - Tuesday

### Surgical Experience: Quadruple Coronary Bypass

I drove to UH Ahuja Medical Center for one last operation to attend before flying back home. I met Dr. Pelletier in the main lobby, and we took the elevators to the OR floor, changed into scrubs, and walked to the operating room. It was going to be a quadruple coronary bypass surgery on a male patient in his sixties. We looked at the coronary angiograms to make sure the right arteries were going to be operated on. Dr. Pelletier confirmed that the LAD, PDA, PLB and RCA were occluded in various degrees. After the patient was put under anesthesia, covered with sterile drapes and the surgical equipment was ready, it was time to scrub in, and this time I was going to be standing by the operating table not to only observe, but also assist.

With the sterile gown and size 8 gloves on, it was time for the first incision. Dr. Pelletier used the knife to make a median incision and then the cautery to cut through the fat tissue and cauterize blood vessels. Then he took the saw and cut open

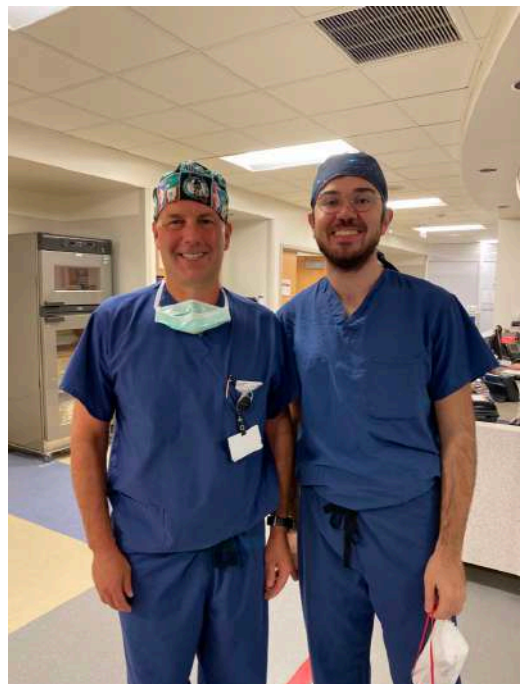

Figure 36: Dr. Pelletier and I on the OR floor

the sternum. We pulled on the opposite wings of the sternum to expand the surgical site. He used the cautery again to stop the bleeding of more blood vessels that were impossible to see. Dr. Pelletier then dissected the pericardium, while I used the suction to remove the pericardial fluid. He then started working on finding and extracting the LIMA, while the surgical assistants were doing the same on the right saphenous vein (SVG). When the grafts were ready, the cannulas were placed into appropriate sites and CPB was established. Dr. Pelletier first anastomosed the SVG to the PLB and then to the PDA sequentially. He then used the remaining half of the graft to anastomose it to the RCA. The last artery to be bypassed was the LAD, for which the LIMA was going to be used, with the proximal end still connected to the left subclavian artery. The doppler was brought to confirm that the blood flow through the arteries were optimal. After everything seemed to be in order, the patient was closed, and the surgery was over.

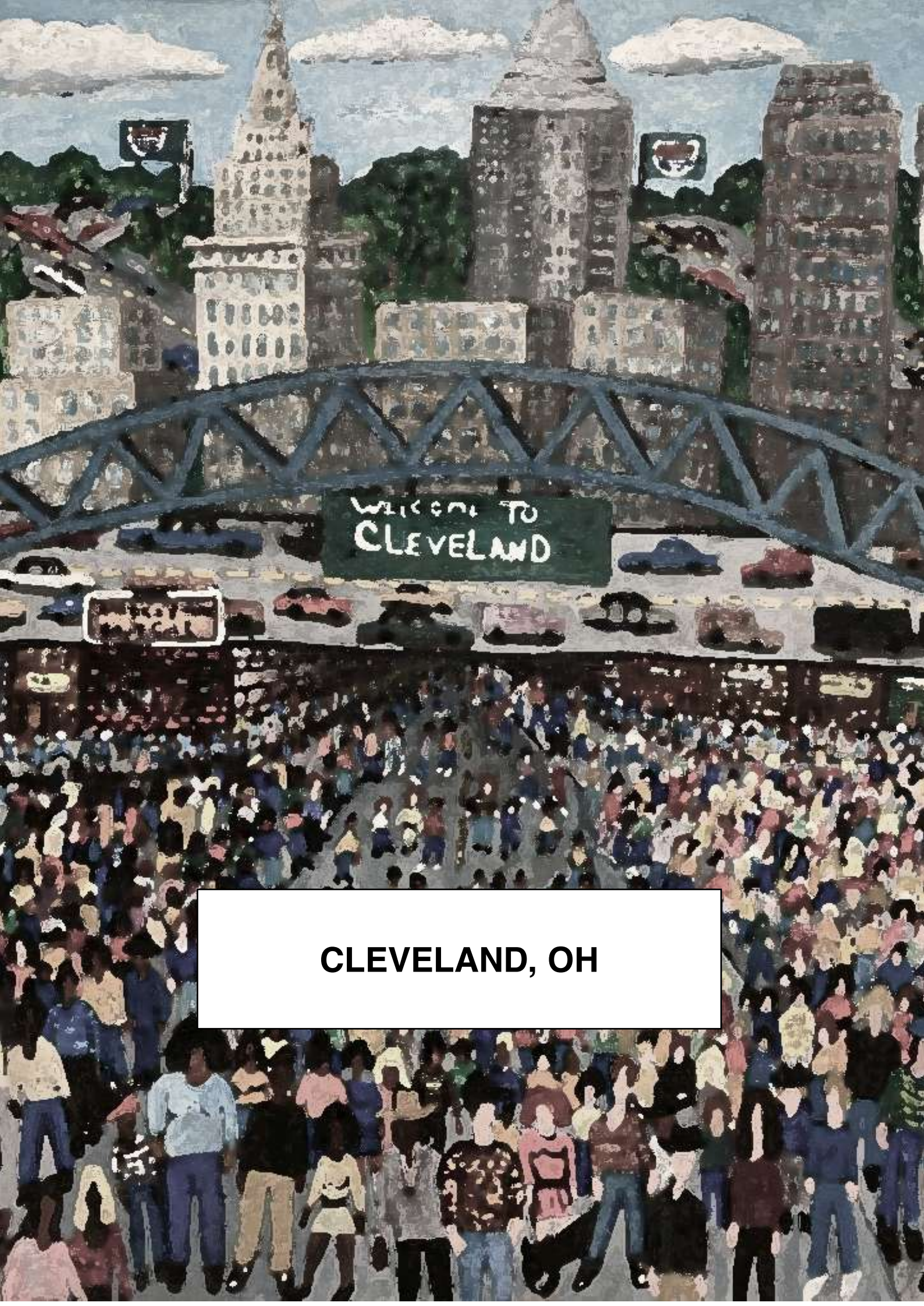### **Farewell to the Cardiac Surgery Team**

Last days are always bittersweet. After spending a whole month at UH with valued cardiac surgeons, cardiologists, nurses, residents and many other people, my time in Cleveland came to an end. Before leaving Ahuja, I took a few moments to express my gratitude to Dr. Pelletier and thanked him for a very instructive month and giving me the opportunity to observe in his department. Then I drove straight to UH Cleveland Medical Center to say goodbye to the surgeons I could find. The first person I saw was the smiling face of Dr. Rushing. I thanked him for being so welcoming, friendly, and instructive in the operating room these past five weeks. The next person I could find was Dr. Baeza; he was as approachable and *chill* as always. I once again thanked him for a wonderful month. We shared a bit of memories and bid each other farewell. I walked the corridor and knocked on the doors of Doctors Abu-Omar and Elgudin, but they weren't around. I would've told them what their kindness and willingness to teach during the time I was at the hospital meant to me.

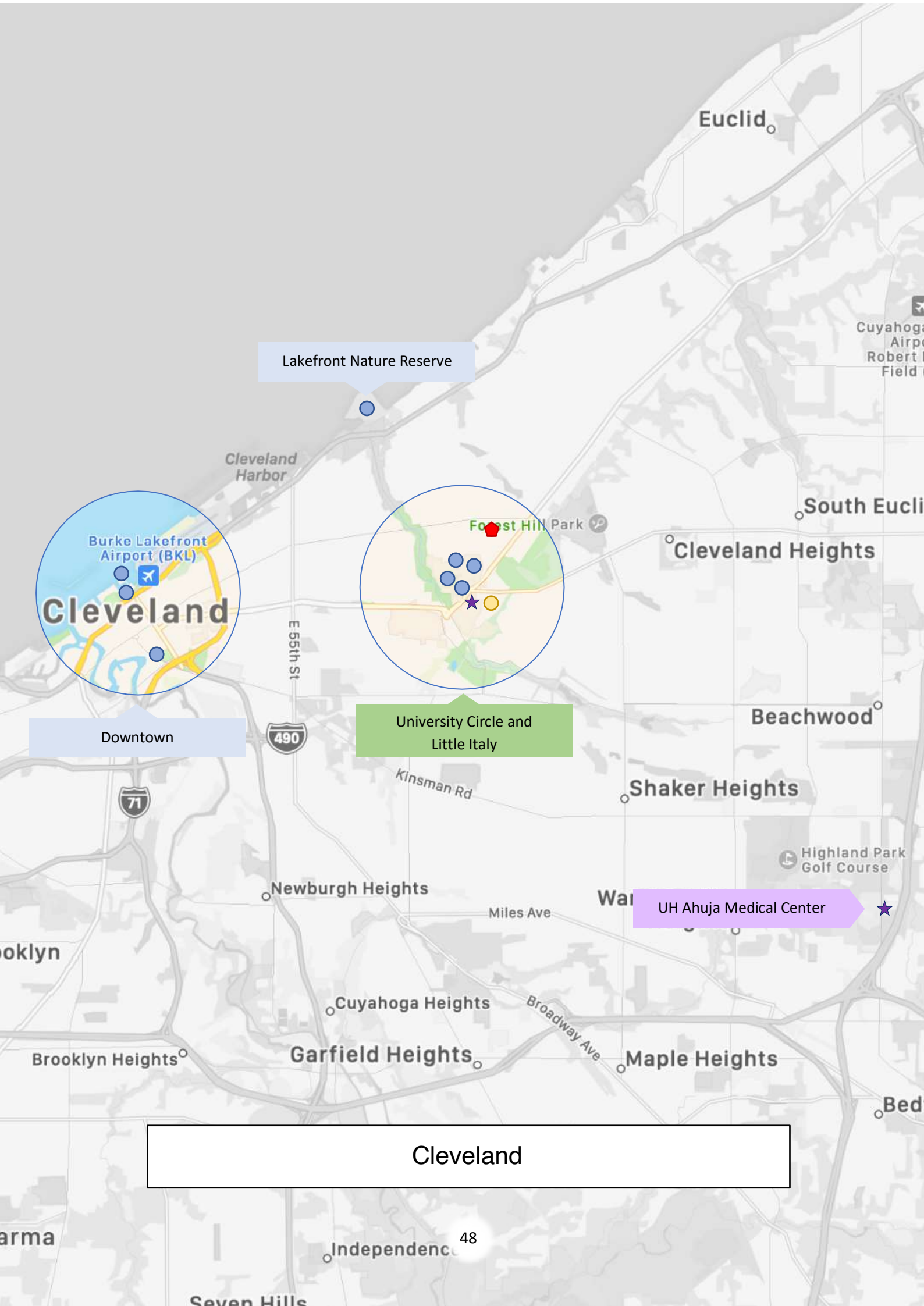
As I walked out of the main entrance and headed to the parking garage, I took one last look at the hospital. And just like that, my month at University Hospitals was over.



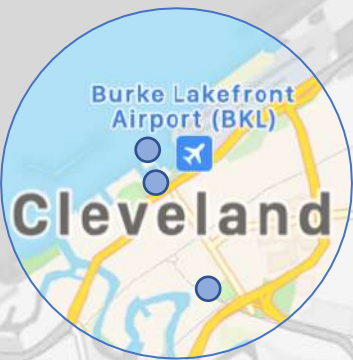
Figure 37: UH Cleveland Medical Center



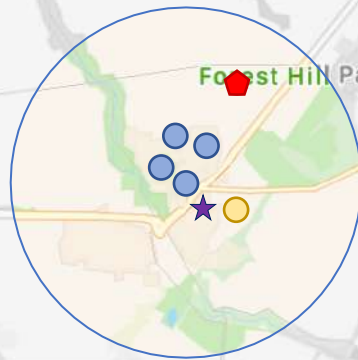
**CLEVELAND, OH**



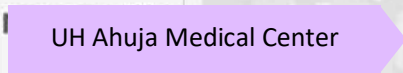
Lakefront Nature Reserve



Downtown



University Circle and  
Little Italy



UH Ahuja Medical Center

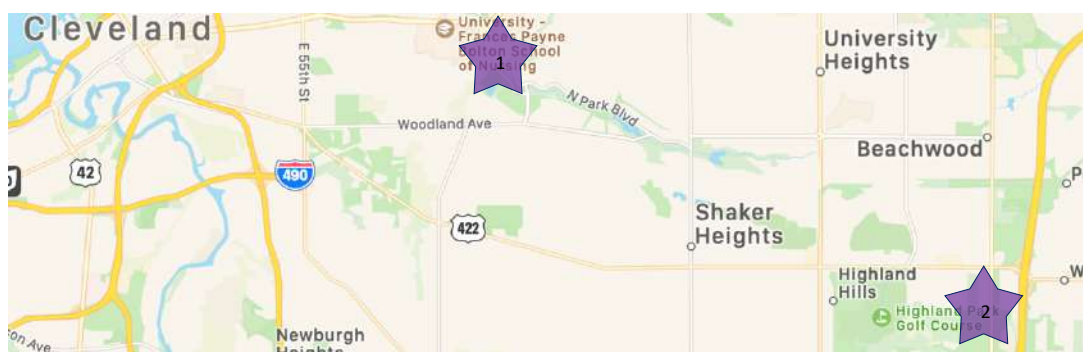
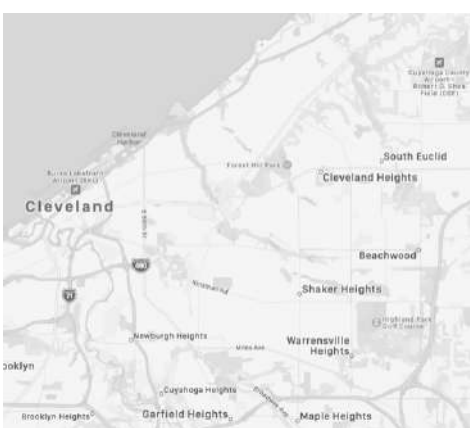Cleveland



(1) Standing in front of UH Cleveland Main Campus



(2) UH Ahuja Medical Center



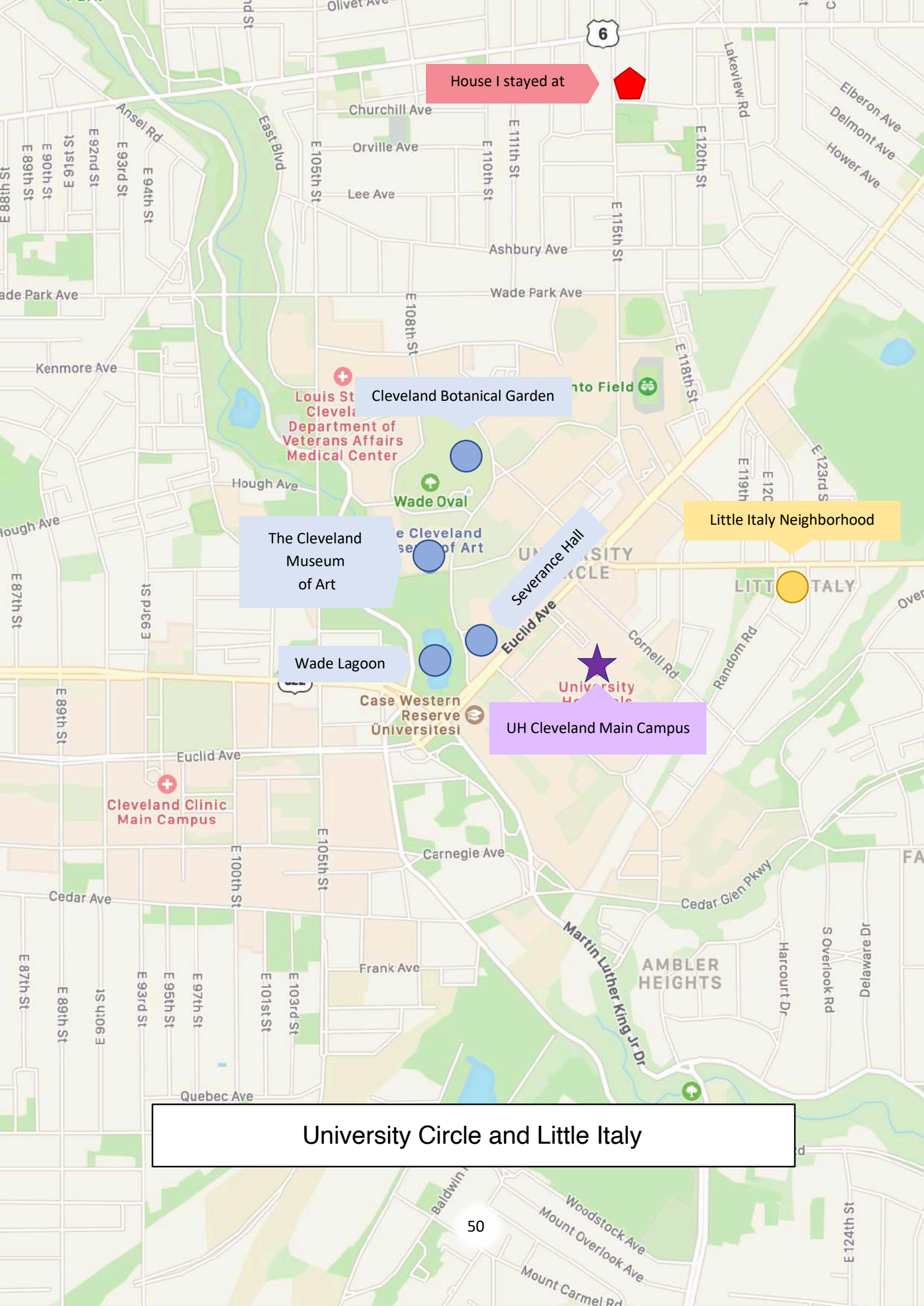
Cleveland



Dr. Markowitz and I in his backyard



The Baeza Family and I, after a pleasant dinner in their house



House I stayed at

Cleveland Botanical Garden

The Cleveland  
Museum  
of Art

Wade Lagoon


UH Cleveland Main Campus

Little Italy Neighborhood

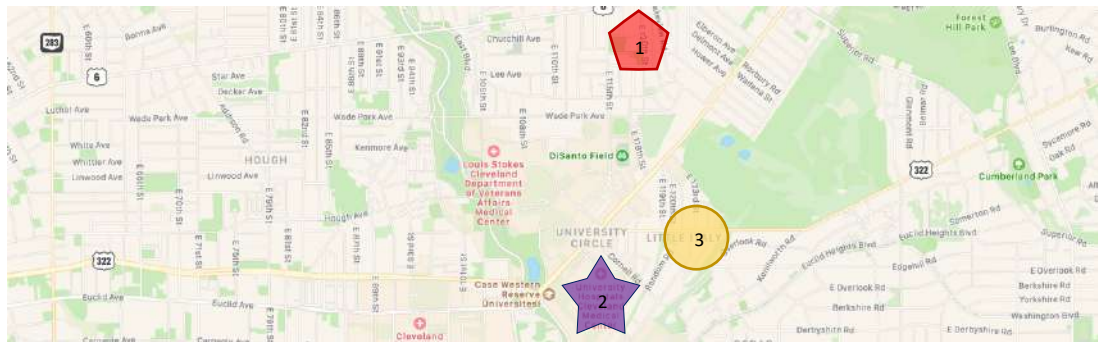
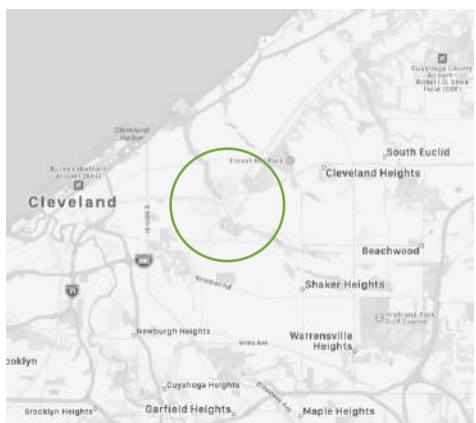
University Circle and Little Italy



(1) The house I stayed at



(1) My room



University Circle and Little Italy




(3) Little Italy



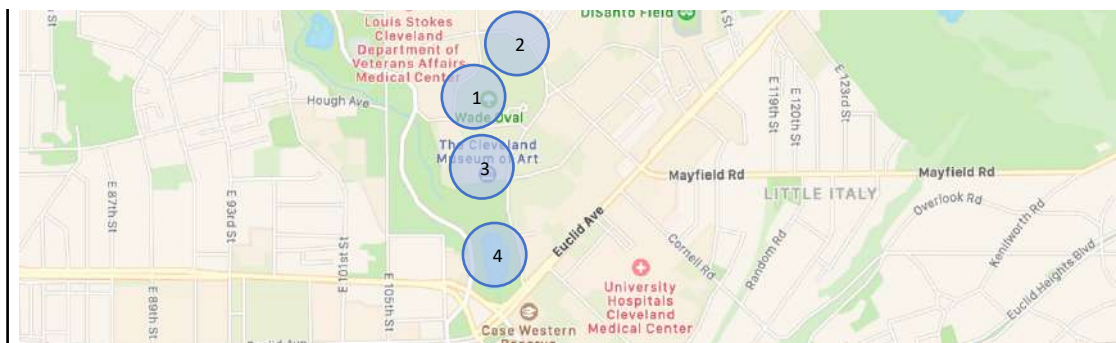
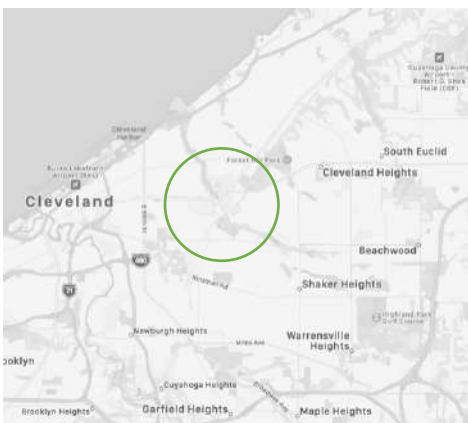
(1) University Circle Sign



(2) Western Reserve Herb Society Herb Garden in Cleveland Botanical Garden



(2) Madagascar Glasshouse in Cleveland Botanical Garden



## University Circle



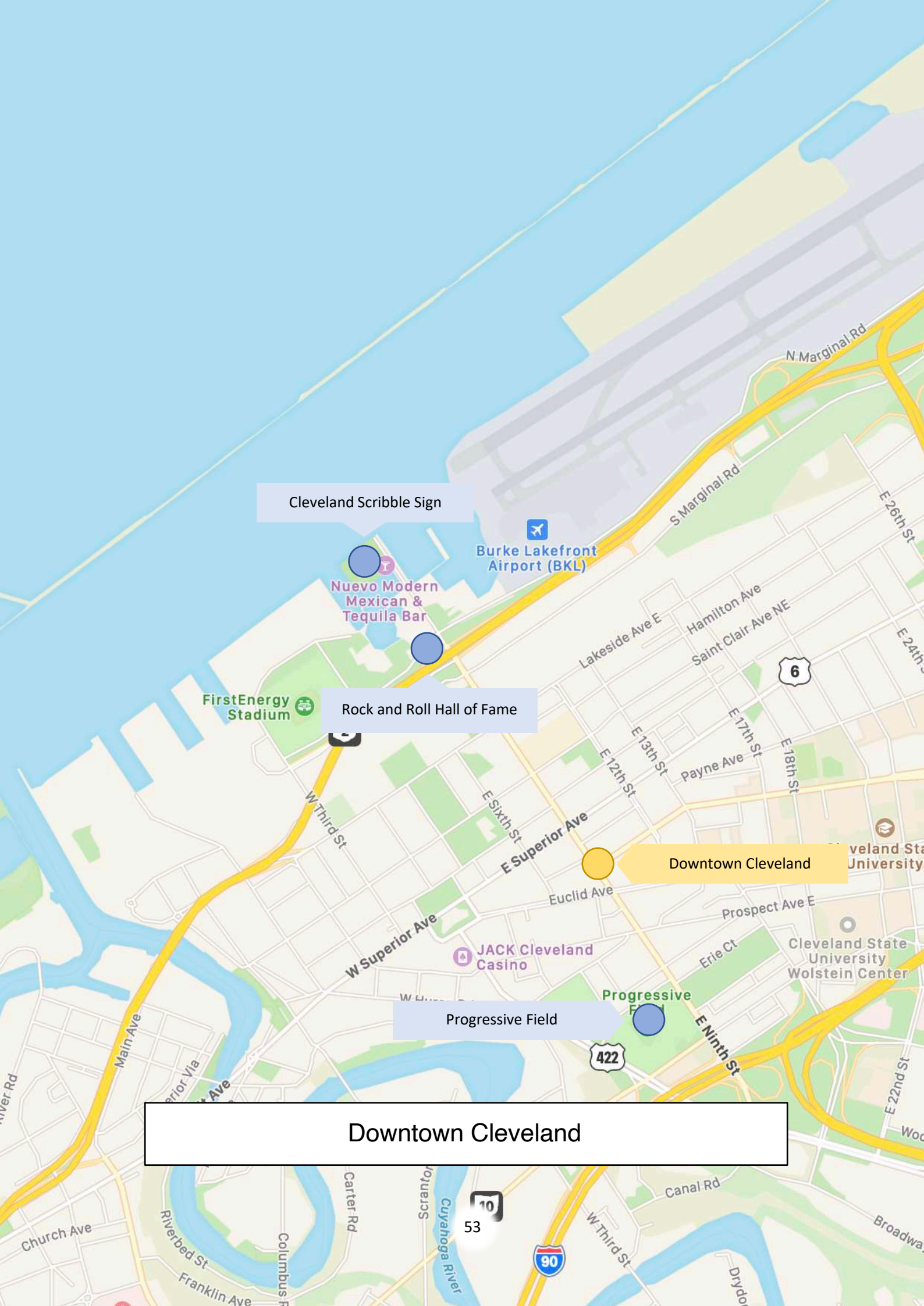
(3) Cleveland Museum of Art



(4) Wade Lagoon



(3) Armor Court in Cleveland Museum of Art



Cleveland Scribble Sign

Nuevo Modern  
Mexican &  
Tequila Bar

Burke Lakefront  
Airport (BKL)

FirstEnergy  
Stadium

Rock and Roll Hall of Fame

Downtown Cleveland

JACK Cleveland  
Casino

Progressive Field

Progressive  
Field

Cleveland State  
University  
Wolstein Center

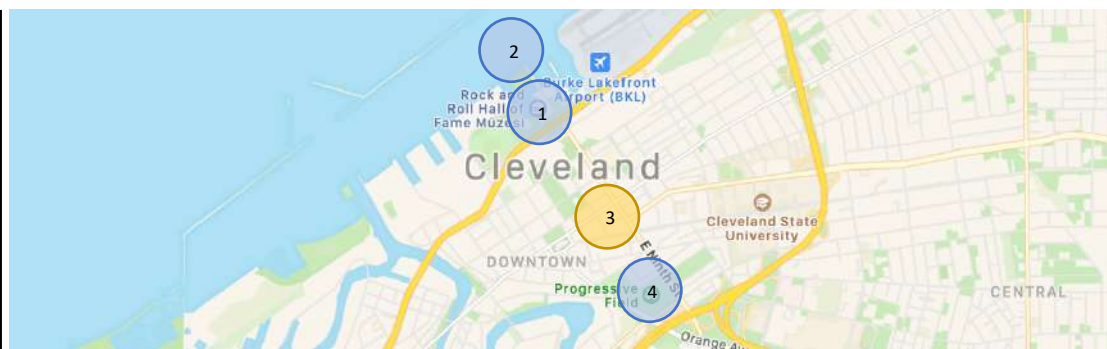
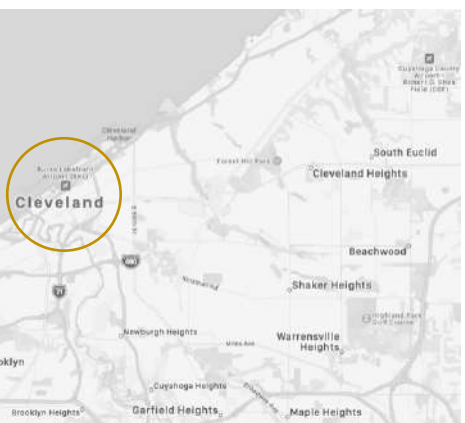
Downtown Cleveland



(1) Rock and Roll Hall of Fame



(2) Standing in front of Cleveland Scribble Sign by the Lake Erie



Downtown



(3) View of Downtown Cleveland from North Coast Harbor



(4) Progressive Field, Home of the Indians

## REFERENCES

1. Mayo Foundation for Medical Education and Research. (2021, June 6). *Congenital heart disease in adults*. Mayo Clinic. <https://www.mayoclinic.org/diseases-conditions/partial-anomalous-pulmonary-venous-return/cdc-20385691#dialogId2892233>.
2. Cheung AT, Stafford-Smith, M, Heath M. Initiation of cardiopulmonary bypass. In: UpToDate, Post, TW (Ed), UpToDate, Waltham, MA, 2021
3. Cheung AT, Stafford-Smith, M, Heath M. Management of cardiopulmonary bypass. In: UpToDate, Post, TW (Ed), UpToDate, Waltham, MA, 2021
4. Fitzsimmons MG. Weaning from cardiopulmonary bypass. In: UpToDate, Post, TW (Ed), UpToDate, Waltham, MA, 2021
5. Ghadimi K, Welsby IJ. Blood management and anticoagulation for cardiopulmonary bypass. In: UpToDate, Post, TW (Ed), UpToDate, Waltham, MA, 2021
6. Gaasch WH. Clinical manifestations and diagnosis of chronic aortic regurgitation in adults. In: UpToDate, Post, TW (Ed), UpToDate, Waltham, MA, 2021
7. Wright MJ, Connolly HM. Genetics, clinical features, and diagnosis of Marfan syndrome and related disorders. In: UpToDate, Post, TW (Ed), UpToDate, Waltham, MA, 2021
8. Hoit BD. Constrictive pericarditis. In: UpToDate, Post, TW (Ed), UpToDate, Waltham, MA, 2021
9. Prakash B, et al. (2017). The Society of Thoracic Surgery Risk Score as a Predictor of 30-Day Mortality in Transcatheter vs Surgical Aortic Valve Replacement: A Single-Center Experience and its Implications for the Development of a TAVR Risk-Prediction Model. *Journal of Invasive Cardiology*, 29(3), 109–114.
10. Aster JC, Stone RM. Clinical manifestations and diagnosis of myelodysplastic syndromes (MDS). In: UpToDate, Post, TW (Ed), UpToDate, Waltham, MA, 2021
11. Otto CM. Clinical manifestations and diagnosis of chronic mitral regurgitation. In: UpToDate, Post, TW (Ed), UpToDate, Waltham, MA, 2019
12. Gaasch WH. Management and prognosis of chronic secondary mitral regurgitation. In: UpToDate, Post, TW (Ed), UpToDate, Waltham, MA, 2019
13. Gaasch WH. Pathophysiology and natural history of chronic mitral regurgitation. In: UpToDate, Post, TW (Ed), UpToDate, Waltham, MA, 2020
14. Antoine, C., Mantovani, F., Benfari, G., Mankad, S. V., Maalouf, J. F., Michelena, H. I., & Enriquez-Sarano, M. (2018). Pathophysiology of degenerative mitral regurgitation. *Circulation: Cardiovascular Imaging*, 11(1). <https://doi.org/10.1161/circimaging.116.005971>
15. Katz, W. E., Conrad Smith, A. J., Croc, F. W., & Cavalcante, J. L. (2017). Echocardiographic evaluation and guidance FOR MitraClip procedure. *Cardiovascular Diagnosis and Therapy*, 7(6), 616–632. <https://doi.org/10.21037/cdt.2017.07.04>
16. Kramer CM. Villines TC. Coronary artery calcium scoring: Image acquisition and clinical utilization. In: UpToDate, Post, TW (Ed), UpToDate, Waltham, MA, 2020

17. Hijazi ZM. Saw J. Atrial fibrillation: Left atrial appendage occlusion. In: UpToDate, Post, TW (Ed), UpToDate, Waltham, MA, 2021
18. Lee R. Surgical ablation to prevent recurrent atrial fibrillation. In: UpToDate, Post, TW (Ed), UpToDate, Waltham, MA, 2021
19. Mazzitelli, D., Fischlein, T., Rankin, J. S., Choi, Y.-H., Stamm, C., Pfeiffer, S., Pirk, J., Detter, C., Kroll, J., Beyersdorf, F., Griffin, C. D., Shrestha, M., Nöbauer, C., Crooke, P. S., Schreiber, C., & Lange, R. (2015). Geometric ring annuloplasty as an adjunct To aortic valve REPAIR: Clinical investigation of the haart 300 device. *European Journal of Cardio-Thoracic Surgery*, 49(3), 987–993. <https://doi.org/10.1093/ejcts/ezv234>
20. *Breakthrough innovation: The haart Aortic Annuloplasty Device cleared by the FDA.* Heart Valve Surgery. (2020, September 17). <https://www.heart-valve-surgery.com/haart-annuloplasty-ring.php>.
21. Otto CM. Clinical manifestations and diagnosis of aortic stenosis in adults. In: UpToDate, Post, TW (Ed), UpToDate, Waltham, MA, 2020
22. Gaasch WH. Indications for valve replacement in aortic stenosis in adults. In: UpToDate, Post, TW (Ed), UpToDate, Waltham, MA, 2020
23. Braverman AC. Clinical manifestations and diagnosis of bicuspid aortic valve in adults. In: UpToDate, Post, TW (Ed), UpToDate, Waltham, MA, 2019
24. Gaasch WH. Natural history, epidemiology, and prognosis of aortic stenosis. In: UpToDate, Post, TW (Ed), UpToDate, Waltham, MA, 2020
25. Birks EJ. Intermediate- and long-term mechanical circulatory support. In: UpToDate, Post, TW (Ed), UpToDate, Waltham, MA, 2020
26. Gaasch WH. Overview of the management of mitral stenosis. In: UpToDate, Post, TW (Ed), UpToDate, Waltham, MA, 2020
27. Otto CM. Clinical manifestations and diagnosis of rheumatic mitral stenosis. In: UpToDate, Post, TW (Ed), UpToDate, Waltham, MA, 2020
28. Meyer TE. Gaasch WH. Pathophysiology and natural history of mitral stenosis. In: UpToDate, Post, TW (Ed), UpToDate, Waltham, MA, 2019
29. Eleid MF. Surgical and investigational approaches to management of mitral stenosis. In: UpToDate, Post, TW (Ed), UpToDate, Waltham, MA, 2019
30. Zühlke L. Peters F. Clinical manifestations and diagnosis of rheumatic heart disease. In: UpToDate, Post, TW (Ed), UpToDate, Waltham, MA, 2021
31. Carroll JD. Percutaneous mitral balloon valvotomy for mitral stenosis. In: UpToDate, Post, TW (Ed), UpToDate, Waltham, MA, 2018
32. Sika-Paotonu D, Beaton A, Raghu A, et al. Acute Rheumatic Fever and Rheumatic Heart Disease. 2017 Mar 10 [Updated 2017 Apr 3]. In: Ferretti JJ, Stevens DL, Fischetti VA, editors. *Streptococcus pyogenes : Basic Biology to Clinical Manifestations* [Internet]. Oklahoma City (OK): University of Oklahoma Health Sciences Center; 2016-. Available from: <https://www.ncbi.nlm.nih.gov/books/NBK425394/>

## IMAGE REFERENCES

Figure 1: Mayo Clinic. (2021). Partial Anomalous Pulmonary Venous Return.  
<https://www.mayoclinic.org/diseases-conditions/partial-anomalous-pulmonary-venous-return/cdc-20385691#dialogId2892233>

Figure 2: Searless, B. Hefner, K. (2021). Intracardiac and Vascular Cannulae Utilized During Cardiopulmonary Bypass.  
[https://www-uptodate-com.lproxy.yeditepe.edu.tr/contents/initiation-of-cardiopulmonary-bypass?source=bookmarks\\_widget#H2346121908](https://www-uptodate-com.lproxy.yeditepe.edu.tr/contents/initiation-of-cardiopulmonary-bypass?source=bookmarks_widget#H2346121908)

Figure 3: Searless, B. Hefner, K. (2021). Cardiopulmonary Bypass Setup  
[https://www-uptodate-com.lproxy.yeditepe.edu.tr/contents/initiation-of-cardiopulmonary-bypass?source=bookmarks\\_widget#H2346121908](https://www-uptodate-com.lproxy.yeditepe.edu.tr/contents/initiation-of-cardiopulmonary-bypass?source=bookmarks_widget#H2346121908)

Figure 4: Neale T. (2017). Prosthesis-Patient Mismatch After Aortic Valve Replacement Declining Tied to Poorer Survival  
<https://www.tctmd.com/news/prosthesis-patient-mismatch-after-aortic-valve-replacement-declining-tied-poorer-survival>

Figure 5: Oxford Medicine. Definition of aortic root and ascending aortic phenotypes and mechanisms of aortic regurgitation (AR) (echocardiographic view) and direction of the regurgitant jet (Doppler view).  
<https://oxfordmedicine.com/oxford/fullsizeimage?imageUri=%2F10.1093%2Fmed%2F9780198784906.001.0001%2Fmed-9780198784906-graphic-31002-full.gif&uriChapter=%2F10.1093%2Fmed%2F9780198784906.001.0001%2Fmed-9780198784906-chapter-765>

Figure 6: Ahmed M. (2017). Mechanical and Tissue Mitral Valves  
<https://myheart.net/articles/heart-valve-surgery-mechanical-vs-bioprosthetic-which-is-better/>

Figure 7: Karki G. (2020). Marfan syndrome  
<https://www.onlinebiologynotes.com/marfan-syndrome-genetics-symptoms-diagnosis-and-treatment/>

Figure 8: Vardiman J. (2001). Myelodysplastic Syndrome: Refractory Cytopenia with Multilineage Dysplasia – 3  
<https://imagebank.hematology.org/image/1429/myeloid-neoplasms-myelodysplastic-syndrome-refractory-ctyopenia-with-multilineage-dysplasia--3?type=upload>

Figures 11: Shvelle D. Basic Coronary Angiography  
[http://keck.usc.edu/cardiovascular-medicine-division/wp-content/uploads/sites/140/2017/10/Basic-Coronary-Angiography\\_All-Slides.pdf](http://keck.usc.edu/cardiovascular-medicine-division/wp-content/uploads/sites/140/2017/10/Basic-Coronary-Angiography_All-Slides.pdf)

Figure 12: US Food and Drug Association. (2019) MitraClip NT Clip Delivery System and MitraClip NTR/XTR Clip Delivery System <https://www.fda.gov/medical-devices/recently-approved-devices/mitraclip-nt-clip-delivery-system-and-mitraclip-ntrxtr-clip-delivery-system-p100009s028>

Figure 13: Hellerhoff. (2015). Mitralklappenclips im Röntgenbild  
[https://en.wikipedia.org/wiki/MitraClip#/media/File:Mitralclips\\_-\\_Roe\\_pa\\_-\\_001.jpg](https://en.wikipedia.org/wiki/MitraClip#/media/File:Mitralclips_-_Roe_pa_-_001.jpg)

Figure 14: Abbott Laboratories. (2016). Components of the MitraClip system  
[https://www.researchgate.net/figure/Components-of-the-MitraClip-system-Images-provided-and-adapted-from-Abbott-Laboratories\\_fig1\\_311529140](https://www.researchgate.net/figure/Components-of-the-MitraClip-system-Images-provided-and-adapted-from-Abbott-Laboratories_fig1_311529140)

Figure 15: ReserachGate. (2009) Illustration of transapical valve implantation

[https://www.researchgate.net/figure/Illustration-of-transapical-valve-implantation\\_fig3\\_47430243](https://www.researchgate.net/figure/Illustration-of-transapical-valve-implantation_fig3_47430243)

Figure 16: Multimedia Manual of Cardio-Thoracic Surgery. (2012). Aortic arch replacement  
<https://mmcts.org/tutorial/8>

Figure 17: Feigenbaum H, Armstrong WF, Ryan T, eds. Feigenbaum's Echocardiography. 6th ed. Philadelphia, PA: Lippincott Williams & Wilkins; 2005. p673  
<https://academic.oup.com/view-large/figure/38838079/jeq05604.jpeg>

Figure 20: UpToDate. (2021). Classification of aortic dissection  
<https://www.emra.org/emresident/article/aortic-dissection-overview/>

Figure 21: Rothberg MB. (2018).  
<https://consultqd.clevelandclinic.org/coronary-artery-calcium-scoring-a-valuable-tool-in-primary-care/>

Figure 22: Boston Scientific. WATHCMAN FLX™ Left Atrial Appendage Closure (LAAC) device  
<https://www.bostonscientific.com/en-EU/products/laac-system/watchman-flx.html>

Figure 24: American Heart Association Journals. (2001). The right atrial lesion set of the Cox-Maze procedure IV.  
<https://www.ahajournals.org/doi/10.1161/CIRCEP.111.963819>

Figure 25: American Heart Association Journals. (2001). The left atrial lesion set of the Cox-Maze procedure IV.  
<https://www.ahajournals.org/doi/10.1161/CIRCEP.111.963819>

Figure 27: European Journal of Cardio-Thoracic Surgery. (2015). Ring implantation technique.  
<https://academic.oup.com/ejcts/article/49/3/987/2465416>

Figure 29: Abbott. Heartmate 3 continuous-flow left ventricular assist device pump.  
[https://www.jcvaonline.com/article/S1053-0770\(18\)30506-8/fulltext](https://www.jcvaonline.com/article/S1053-0770(18)30506-8/fulltext)

Figure 32: Journal of American Heart Association. (2020).  
<https://www.ahajournals.org/doi/10.1161/JAHA.120.016521>

Figure 33: Binder T. (2021) Apical long axis view from a 2-D echocardiogram shows thickened mitral valve leaflets which have marked limitation of mobility and show doming, with failure to open normally during diastole.

Figures 34: Freeman R. (2021). Parasternal long-axis view showing MAC along the posterior mitral annulus. Parasternal short-axis view of the left ventricle showing posterior aspect of the mitral annulus.  
[https://www-uptodate-com.lproxy.yeditepe.edu.tr/contents/clinical-manifestations-and-diagnosis-of-mitral-annular-calcification?search=.%20Clinical%20manifestations%20and%20diagnosis%20of%20rheumatic%20mitral%20stenosis&topicRef=8173&source=see\\_link#H3345730163](https://www-uptodate-com.lproxy.yeditepe.edu.tr/contents/clinical-manifestations-and-diagnosis-of-mitral-annular-calcification?search=.%20Clinical%20manifestations%20and%20diagnosis%20of%20rheumatic%20mitral%20stenosis&topicRef=8173&source=see_link#H3345730163)

Figure 35: Mayo Clinic. (2021). Balloon valvuloplasty. <https://www.mayoclinic.org/tests-procedures/valvuloplasty/pyc-20384961#dialogId37773755>



University  
Hospitals

26

UNIVERSITY HOSPITALS  
Identification Badge

FOR: Ali Yenigun  
DEPT: Observer  
CODE: 753017  
EXPIRES: 09/02/2021

To Discover